

University of Rajshahi

Rajshahi-6205

Bangladesh.

RUCL Institutional Repository

<http://rulrepository.ru.ac.bd>

Institute of Biological Sciences (IBSc)

PhD Thesis

2012

Cervical Cancer Screening by Simple Visual Inspection After Acetic Acid

Yusuf, Nahid

University of Rajshahi

<http://rulrepository.ru.ac.bd/handle/123456789/759>

Copyright to the University of Rajshahi. All rights reserved. Downloaded from RUCL Institutional Repository.

**CERVICAL CANCER SCREENING BY SIMPLE VISUAL
INSPECTION AFTER ACETIC ACID**



**THESIS SUBMITTED FOR THE DEGREE OF
DOCTOR OF PHILOSOPHY**

SUBMITTED BY

NAHID YUSUF

REGISTRATION NO. M- 19

SESSION 2007-2008

IN THE

INSTITUTE OF BIOLOGICAL SCIENCES

UNIVERSITY OF RAJSHAHI

RAJSHAHI- 6205


BANGLADESH

DECEMBER 2012

Declaration

I hereby declare that the work submitted as thesis entitled '**Cervical Cancer Screening by Simple Visual Inspection after Acetic Acid**' to the Institute of Biological Sciences, University of Rajshahi for the degree of Doctor of Philosophy (PhD), is the result of my own investigations, except where reference has been made to published literatures or to the contribution of other workers. The work had been carried out under supervision of Dr. Jahan Ara Khanam, Professor, Department of Biochemistry and Molecular Biology, University of Rajshahi, Dr. Hasina Akhter, Professor and Head, Department of Obstetrics and Gynaecology, Rajshahi Medical College, Rajshahi. The thesis had not been accepted in substance for any degree and is not being concurrently submitted for any degree to any other University.

December, 2012


(NAHIDYUSUF)

Candidate

Certificate

We hereby certify that the thesis entitled '**Cervical Cancer Screening by Simple Visual Inspection after Acetic Acid**' submitted by Nahid Yusuf for the award of PhD degree in the field of Medical Science, Institute of Biological Science, University of Rajshahi, Bangladesh, is absolutely based on her own work under our direct supervision and guidance. This is also certified that the research work embodied here is original and carried out by Nahid Yusuf. Neither this thesis nor any part of the work has been submitted for any other degree or any other academic award anywhere before.

We would like to say that her research has contributed some new ideas and opening in our research filed.

Jahanara Khanam

Dr. Jahan Ara Khanam,
Professor,
Dept. of Biochemistry and Molecular Biology,
University of Rajshahi

Professoor
Dept. Biochemistry & Molecular Biology
Rajshahi University.

Hasina Akhter

Dr. Hasina Akhter
Professor & Head
Department of Obs. & Gynae
Rajshahi Medical College Hospital

Acknowledgements

All praises for Almighty Allah, the merciful, the beneficent for giving me the opportunity, courage and capability to carry out and to complete this entire thesis work successfully.

I would like to express my heartiest gratitude and profound admiration to my respected supervisor Dr. Jahan Ara Khanam, Professor, Department of Biochemistry and Molecular Biology, University of Rajshahi. I am greatly indebted and grateful for her valuable suggestion, keen supervision, constant guidance and constructive criticism in every step of my work. Without her contribution, the completion of my work would have been impossible.

I am deeply indebted to my co-supervisor Dr. Hasina Akhter, Professor and Head, Department of Gynaecology and Obstetrics, Rajshahi Medical College, Rajshahi, for her guidance, whole hearted cooperation and valuable suggestions during my research work.

I am extremely thankful to Brigadier General Bozle Kader, Director (Ex), Rajshahi Medical College Hospital for giving me permission in doing my study work in this hospital.

I am grateful to Dr. Shah Md. Badruddoza, Professor and Head, Department of Pathology, Rajshahi Medical College, Rajshahi for giving me the opportunity to carryout a part of my research work in Pathology Department providing all facilities.

I would like to express my heartiest thanks to my friend Dr. Rukhshana Akhter Jahan, Lecturer, Department of Pathology, Rajshahi Medical College, Rajshahi for her cordial help, and active cooperation in doing my thesis work.

Heartiest remembrance and thanks to Dr. Jawadul Haque, Professor and Head, Department of Community medicine, Rajshahi Medical College, and Dr. Anayet Ullah, Lecturer, Department of Community medicine, Rajshahi Medical College for their constructive criticism, kind cooperation and statistical analysis which have made this study possible.

I am ever grateful to Dr. Md. Badiuzzaman, Ophthalmologist who gave me first inspiration and valuable suggestion regarding admission in PhD course.

I would like to express my heartiest thanks to Dr. Amzad Hossain, Professor, Department of Finance and Banking, Rajshahi University and to my friend Dr. Farzana Pervin, Professor, Department of Biochemistry and Molecular Biology, Rajshahi University, for their cordial help and whole hearted cooperation regarding admission in PhD course and encouragement in doing my thesis work.

I would like to extend my thanks to Mst. Sufia Khatun, senior staff nurse and other staff of Gynae Outpatient Department, Rajshahi Medical College Hospital, for their constant support and cooperation in collecting samples for this study and also to those patients from whom all the specimens were collected.

I would like to extend my thanks to staffs of the Department of Pathology, Rajshahi Medical College, Rajshahi, for their technical support.

I must express my sincere gratitude to Managing Director, Popular Diagnostic Center Ltd. for providing me laboratory support for HPV-DNA test.


I would like to offer my heartfelt thanks to Director Dr. Tanzima Yeasmin, Ex-Director Professor Dr. Khalequzzaman and other teachers and associate staffs of Institute of Biological Sciences, University of Rajshahi for their overall cooperation.

I express my thanks to Shuvo who particularly digitized many illustrations and diagrams of this thesis work.

I also grateful to Nazmul and Bari for their active cooperation and assistance for typing and computer compose of this thesis with patience and sincerity.

I am grateful to my husband Dr. Md. Ahmed Ali, Associate Professor, Dept. of Neurology, Rajshahi Medical College, Rajshahi for providing me emotional support, patience and cooperation during the long period of my research work. My special thanks to my daughters Anika and Fariha for their support at the crucial moment of the thesis work.

December, 2012


(Nahid Yusuf)

Candidate

Dedicated

To my

Beloved Late Parents

CONTENTS

	Page No
ABSTRACT	i-vi
CHAPTER I GENERAL INTRODUCTION AND REVIEW	1-52
1. Introduction	1
1.1 Cervical cancer	2
1.1.1 Natural history of cervical cancer	5
1.1.2 Clinical feature of CIN and cervical cancer	9
1.1.3 Aetiology of CIN and cervical cancer	10
1.1.4 Management of CIN	13
1.1.5 Appearance of CIN and preclinical invasive carcinoma on VIA	14
1.1.6 Colposcopic appearance of CIN and preclinical invasive carcinoma	15
1.1.7 Histopathological Findings of CIN and cervical carcinoma	18
1.1.8 Pap smear cytological findings of CIN and cervical carcinoma	21
1.2 Prevention of cervical cancer	22
1.2.1 Primary prevention	22
1.2.2 Secondary prevention by screening	23
1.2.3 Guidelines for cervical cancer screening	23
1.2.4 Methods of cervical cancer screening	25
1.2.4 (a) Cytology based screening (Pap smear)	25
1.2.4 (b) Visual inspection of cervix after application of Acetic Acid (VIA) or Lugol's iodine(VILI) based screening	26 28
1.2.4 (c) Colposcopy	29
1.2.4 (d) HPV-DNA based screening	30
1.2.4 (e) Other screening tests: cervicography, Fluorescence Spectroscopy, Down staging	32

	Page No
1.3 Review on research work done on Pap smear, VIA and HPV-DNA test	34
References	41
CHAPTER II STATEMENT OF THE WORK	53-54
2.1 General objective	54
2.2 Specific objectives	54
CHAPTER III EXPERIMENTAL	55-68
3. Materials and Methods	56
3.1 Introduction	56
3.2 Study design and participant	56
3.3 Inclusion criteria	56
3.4 Exclusion criteria	56
3.5 Methods of data collection	57
3.6 Outcome measures	57
3.7 Equipments and materials require for VIA	58
Procedure of VIA	59
3.8 Colposcopy	60
Instruments and materials require for colposcopy	60
Procedure of colposcopic examination	61
Steps of colposcopic examination	62
3.9 The technique followed for the Histopathological Examination	63
Preparation of Haematoxylin and Eosin stains (H and E)	64

	Page No
Preparation of Papanicolaou's stain	65
3.10 Data Collection	65
3.11 Statistical analysis	66
 CHAPTER IV Study no I	 69-89
 Early Detection of Cervical Intraepithelial Lesions by Simple Visual Inspection after Acetic Acid among Women Rajshahi Medical College Hospital	
4.1 Introduction	70
4.2 Material and methods	71
4.3 Statistical analysis	72
4.4 Study results	73-82
4.5 Management	83
4.6 Discussion	83
References	86-89
 CHAPTER V Study No 2	 90-106
 Visual Inspection of the Uterine Cervix after application of Acetic Acid in the detection of Cervical Cancer and its Precursors	
5.1 Introduction	91
5.2 Material and methods	91

	Page No
5.3 Statistical analysis	92
5.4 Study results	93-102
5.5 Discussion	103
References	105-106
CHAPTER VII GENERAL DISCUSSION AND CONCLUSION	129-134
References	135-138
APPENDICES	
Appendix - I: Published / communicated work:	i
Appendix - II: Future Prospect of the Study	ii
Appendix - III: Data collection proforma	iii-v

LIST OF FIGURES

Figure No	Title	Page No
1.1	Cervix in relation to upper part of vagina and lower Part of the body of uterus	3
1.2	Effect of HPV proteins E6 and E7 on the cell cycle	7
1.3	Thin acetowhite lesion with irregular margin arising from SCJ, suspicious of CIN I	14
1.4	A moderately dense acetowhite area, with regular margin, suspicious of CIN-II	14
1.5	A circumferential dense acetowhite area, suspicious of CIN-III	15
1.6	Dense, acetowhite lesion with raised margin and irregular, nodular surface suggestive of early invasive carcinoma	15
1.7	Mild to dense acetowhite lesion with fine mosaic Histology indicated CIN I	16
1.8	Dense acetowhite lesion with varying regular colour intensity and coarse mosaics (a) in a CIN II lesion	16
1.9	Dense acetowhite lesion with regular margin and coarse, irregular punctation in a CIN III lesion.	17
1.10	Invasive cervical cancer: irregular surface with atypical blood vessels in the dense acetowhite area	17
1.11	CIN I	18
1.12	CIN II	19
1.13	CIN III/ ca-in-situ	19
1.14	Microinvasive carcinoma	20
1.15	Invasive carcinoma	20
1.16	Invasive cancer: proliferative growth on the cervix	20

	Page No
1.17 Invasive cancer: ulcerated fungating growth on the cervix	20
1.18 cytological appearance of and CINI, II and III	22
1.19 Diagrammatic figure of cytology and histology of CIN and invasive cancer	22
1.20 VIA negative (No acetowhite lesion on the cervix	28
1.21 VIA positive (acetowhite lesion on the cervix in SCJ)	28
1.22 Before application of Lugol's iodine	29
1.23 After application of Lugol's iodine	29
1.24 The Hybrid Capture II HPV test	31
3.1 Equipments and materials require for VIA	58
3.2 Instruments and materials require for of the colposcope	60
4.4.1 Age distribution the screened patients	75
4.4.2 Distribution of symptoms of the screened patients	76
4.4.3 Distribution of speculum examination findings of the screened patients	77
4.4.4 screening result of VIA	80
4.4.5 screening result of Colposcopy	81
5.4.1 Percentage detection of different lesions by VIA	96
5.4.2 Percentage detection of different lesions by Colposcopy	97
5.4.3 Percentage detection of different lesions by histopathology	98
5.4.4 Screening result of VIA and Colposcopy	100
6.5.1 Screening result of VIA	114
6.5.2 Screening result of Paps smear cytology	115
6.5.3 Screening result of HPV DNA test	116
6.5.4 Histopathological findings of screening positive cases	118
6.5.5 Pap smear cytological diagnosis of the study patients	119
6.5.6 Histopathological findings of screening positive cases	120

LIST OF TABLES

Table No	Title	Page No
4.4.1	Findings regarding the risk factors of cervical cancer in VIA positive cases	78
4.4.2	Percentage detection of different lesions by VIA, Colposcopy and Histopathology	82
5.4.1	Percentage detection of different lesions by VIA, Colposcopy and Histopathology	95
5.4.2	Screening results of VIA and Colposcopy	99
5.4.3	Screening results of VIA for different grades of CIN	101
5.4.4	Screening results of Colposcopy for different grades of CIN	102
6.5.1	Histopathological findings of screening positive cases	117
6.5.2	VIA and its relation to Histopathology	121
6.5.3	Pap smear cytology and its relation of Histopathology	122
6.5.4	HPV DNA test and its relation of Histopathology	123
6.5.5	Statistical analysis of VIA, Pap smear cytology and HPV-DNA test	124

Abbreviations

ACCP	Alliance for Cervical Cancer Prevention
ACOG	American College of Obstetrics and Gynecologist
AIDS	Acquired Immune Deficiency Syndrom
ASCUS	Atypical Squamous cell of Undetermined Significant
CGIN	Cervical Glandular Intraepithelial Neoplasia
CIN	Cervical Intraepithelial Neoplasia
CIS	Carcinoma In Situ
DES	Diethylstilbestrol
DNA	Deoxyribonucleic Acid
H & E	Haematoxylin and Eosin
HIV	Human Immune Deficiency Virus
HPV	Human Papilloma Virus
HR	High Risk
HSIL	High grade Squamous Intraepithelial Lesion
HSV	Herpes Simplex Virus
ICC	Invasive Cervical Cancer
LBC	Liquid Based Cytology
LEEP	Loop Electrosurgical Excision Procedure
LSIL	Low grade Squamous Intraepithelial Lesion
LLETZ	Large Loop Excision of the Transformation Zone
LYS	Per Year of Live Saved
MCH	Maternal and Child Health
NPV	Negative predictive value
OCP	Oral contraceptive pill
OPD	Out Patient Department
PCR	Polymerase Chain Reaction

PPV	Positive predictive value
RB gene	Retinoblastoma gene
RMCH	Rajshahi Medical College Hospital
RLU	Relative Light Units
SCJ	Squamocolumnner junction
SIL	Squamous Intraepithelial Lesion
SPSS	Statistical Package for the Social Science
STD	Sexually Transmitted Disease
STI	Sexually Transmitted Infection
TZ	Transformation zone
VIA	Visual Inspection with Acetic Acid
VIAM	Visual Inspection with Acetic Acid with Magnification
VILI	Visual Inspection with Lugol's Iodine
WHO	World Health Organization

Abstract

Cervical cancer kills almost 250,000 women each year in developing countries, representing more than 80% of the worldwide deaths due to this preventable cancer. Almost all cases of cervical dysplasia or cervical cancer are caused by Human Papilloma Virus (HPV), which is spread through sexual contact. Three main factors have been postulated to influence the progression of low-grade cervical dysplasia to high-grade lesion and cervical cancer. These include the type and duration of viral infection; host conditions that compromise immunity, such as multiparity or poor nutritional status and environmental factors such as smoking, oral contraceptive pill use or vitamin deficiencies. In addition, various gynecologic factors, including early age of first intercourse and number of sexual partners significantly increase the risk for cervical cancer.

Cervical cytology has been success in the developed world in reducing the incidence and mortality of cervical cancer. But in most developing countries, despite decades of effort, cytology-based cervical cancer prevention programs have not been successful for several different reasons like inadequate coverage of a large population, specially the rural and underdeveloped sections of society, lack of adequate infrastructure, including medical and paramedical staff, laboratory and transport facilities, and trained cytotechnicians and cytopathologists, poor compliance with follow-up visits and the low sensitivity of the Pap smear resulting in a high false-negative rate of 9 to 40%. The sensitivity of the Pap smear has been found to be even lower in developing countries. The possible reason for this may be the large percentage of cervicitis and inflammatory smears, which mask mild dysplasia.

Because of the burden of cervical cancer is the highest in such low-resource settings, clinicians in developed countries began to explore alternative methods

that meet all the basic criteria of a good screening test (e.g. effective, available, affordable, safe and practical). Recently, attention has been focused on visual inspection of the cervix with acetic acid (VIA), as the most promising alternative to cytology for low-resource settings. Numerous studies have been conducted on its accuracy and its ability to detect cervical lesions when compared with other techniques, both conventional and non conventional. Author comparing VIA with cytology noted that the overall usefulness of VIA compares favorably with that of the Pap test and HPV-DNA test.

As cervical cancer is a major health problem among women of Bangladesh, its screening program has been discussed at national level. In July 2004, the Government of Bangladesh with the support of UNFPA has taken on initiative to develop cervical cancer screening program in Bangladesh based on VIA test as pilot program.

The department of Obstetrics and Gynaecology of Bangabandhu Sheikh Mujib Medical University (BSMMU), Dhaka along with other medical colleges and institutes provided training to service providers. This training aimed at developing the skills of service provider working at Maternal and Child Welfare Centres, District Hospitals and selected Union Health and Family Welfare Centres, so that they can screen cervical cancer and identify precancerous conditions of the cervix and assist in managing all these cases through referral and follow up mechanism.

As a part of this pilot program, cervical cancer screening program has started in Rajshahi Medical College Hospital since September '05. This study was done from July 2007 to June 2010 as a part of this ongoing screening program. The main objective of this study was to consider whether the aided visual inspection could be used as an alternative modality to detect precancerous and early cancerous lesions of cervix.

Ethical clearance of this research work was approved by Ethical Review Committee of Research cell of Rajshahi Medical College, Bangladesh (ref. RMC/ER/2010-2013/01)

This study was divided into three phases:

In first phase of the study, 5593 eligible women attending Gynae OPD of Rajshahi Medical College Hospital (RMCH) for gynecological problems were examined by VIA from July 2007 to December 2008. In this study phase the performance of VIA was evaluated in the detection of precancerous and early cancerous lesions of cervix.

For epidemiological study, data had been collected regarding age of first coitus and first delivery, history of extramarital exposure and sexually transmitted infection, use of contraceptive methods, family history of cancer and socioeconomic status from VIA positive cases. Out of 442 VIA positive cases, 203(46%) women had first coitus between 12 to 15 years and second highest 177(40%) were between 16 to 20 years. More than half of the patients, 274(62%) delivered their first baby between 15-20 years, age below 15 years was 53(12%), 88(20%) between 21-25 years and 27(06%) delivered first above 25 years. Regarding history of exposure, 75(17%) had extramarital exposure. Previous history of sexually transmitted infection was present only 09(2%) cases. The oral contraceptive pill, Injectable contraceptive and barrier methods used were 339 (54%), 75 (17%), 44 (10%) respectively. 84 (19%) patients did not use any contraceptive. Regarding socioeconomic status, most of the patients 256 (58%) belonged to lower middle group and second highest, 111 (25%) was middle group. Among the study patients, 671(12%) had no symptoms, only they came for screening purpose. Intermenstrual bleeding, post coital bleeding, heavy irregular vaginal bleeding were found in 1958 (35%), 783(14%), 336 (06%) women respectively. Dirty brown white discharge was the complaints

in more than half of the cases 3020 (54%), lower abdominal pain was the second highest complaints 2460 (44%), and other symptoms like backache, dysuria, dyspareunia etc. were present in 3356 (60%) patients.

On speculum examination, apparently healthy cervix was observed in 2908 (52%) cases. Cervical lesions such as erosion or ectropion, polyp, cauliflower like growth and nodular/ nabothian cysts were observed in remaining of cases.

Out of 5593 patients screened, 5151 (92.8%) were VIA negative and 442 (7.2%) were VIA positive (CIN I 405, CIN II 20, CIN III 07 and invasive carcinoma 10). VIA positive patients were colposcopically evaluated (n=442). Among them, 228 (51.59%) were colposcopically normal and 214 (48.40%) had different stages CIN and carcinoma cervix (CIN I 149, CIN II 27, CIN III/ carcinoma in-situ 09 and invasive carcinoma 12 cases). Out of 214 colposcopically positive patients biopsied, 156 (72.90%) had chronic cervicitis (chronic inflammatory changes in cervix), 41 (16.8%) patients had a final diagnosis of CIN lesions (CIN I 29, CIN II 06, CIN III/carcinoma in-situ 06) and seventeen (7.94%) cases of invasive carcinoma.

From the above findings, it was observed that out of 442 VIA positive cases, 214 cases were colposcopically positive and out of 214 colposcopically positive cases ultimately 58 cases had histologically proven CIN lesion and invasive cervical carcinoma.

In second phase of study, sensitivity, specificity, and predictive values of VIA and colposcopy were determined among 540 eligible women who attended to Gynaec OPD of RMCII from January 2009 to December 2009.

Results of this study phase showed that the sensitivity of VIA for biopsy proven CIN I or worse lesion was 68.08%, specificity 69.73%, positive predictive value 32.16% and negative predictive value 91.20%. On the other hand, out of 117

biopsies with positive results, 102 were detected on colposcopy giving sensitivity of 87.18%, specificity 76.83%, positive predictive value 51.0%, and negative predictive value 95.59% respectively.

There were 30 cases of biopsy proven high-grade lesions and 28 of these were detected on VIA giving a high sensitivity rate ranging from 92-100% and negative predictive value 100%. Similarly sensitivity of colposcopy in picking up high-grade lesions were 96-100% and negative predictive value 100%.

In third phase of the study, the association of Human Papillomavirus (HPV) in precancerous and cancerous lesions of cervix detected by VIA and Pap smear cytology were evaluated. This study phase also carried out in Gynae OPD of RMCH among 115 patients from January 2010 to June 2010.

Results of this study phase showed, the test parameters for VIA were sensitivity of 94.11%, specificity of 57.57%, positive predictive value of 12.2%, and negative predicative value of 99.7%. The test parameters for Pap smear were sensitivity of 64.71%, specificity of 94.29%, positive predictive value of 51.7% and negative predicative value of 99.8%. The test parameters for HPV DNA test were sensitivity of 82.35% and specificity of 84.85%, positive predictive value of 73.68% and negative predicative value of 90.32%. VIA and HPV-DNA tests detected all cases of high-grade lesions (CIN II and III) and carcinoma.

From the above findings, it has been observed that VIA can identify most of the true precancerous and cancerous lesions of the cervix. The sensitivity for low-grade lesions was found to be low (84%), On the other hand, sensitivity for high-grade lesions were high, ranging from 92-100% and negative predictive value were 100%. Test negative would be reassured that most probably they do not have high-grade lesions or cancer.

It has also been observed that, VIA and HPV-DNA tests detected all cases of high-grade lesions (CIN II and III) and carcinoma. The negative predictive value for VIA was 95% reflecting a chance of missing CIN/cancer was 5%. On the other hand, negative predictive value for Pap smear was 83.78% reflecting that probability of not having CIN/cancer was 83.78% and the chance of missing CIN/cancer was 16.22%. This rate is very high and not suitable for cancer screening. HPV-DNA test showed strong association with high-grade lesions and carcinoma of the cervix.

Finally, it can be concluded that VIA has arisen, as a promising alternative for developing countries because it is inexpensive, fast, requires a low level of training and no special equipment. VIA performed by field level health and family planning workers may be considered as a feasible method for screening of cervical cancer in the present socioeconomic context of Bangladesh as it fulfills all the criteria of an ideal screening method.

In view of the paucity of trained manpower in the field of cytology, lack of central cytology laboratories, loss of follow up of women after cytology test on one side and the relative ease of doing acetic acid application, lower cost involvement in biopsying and treating the patient in same set up during the same visit may make screening by acetic acid application a suitable alternative in resource poor settings. Only such type of screening may reduce the cervical cancer burden tremendously in our country.

Chapter-I

GENERAL INTRODUCTION AND REVIEW

1. Introduction:

Cervical cancer is the second most prevalent cancer among women world wide, accounting for nearly 452000 new cases per year.¹ Though no reliable statistical data about cancer is available, it is proved that cervical cancer is the most common cancer among women in Bangladesh and has annual incidence nearly 11956 which constitutes about 22-29% of the female cancers in different areas of the country.^{2,3} All the tertiary level hospitals and institutes of this country are carrying a large load of cervical cancer patients because most of the cervical cancers are diagnosed at the advanced stage. The problem in our country is particularly acute because of poverty, early marriage, multiple marriage, high parity, poor nutrition, illiteracy and lack of basic knowledge of the people about health matters.⁴

Most women who die from cervical cancer, particularly in developing countries, are usually in the prime of their life. They may be raising children, caring for their family and contributing to the social and economic life of their towns or villages. Their death is both personal tragedy and an unnecessary loss to their family and community. 'Unnecessary' because there is compelling evidence that cervical cancer is one of the most preventable and treatable forms of cancer as long as it is detected early and managed effectively.⁵

The cervix undergoes normal changes from birth until after menopause. The cervical transformation zone is the area where the great majority of precancer and cancer originate. The usual 10-20 years natural history of progression from mild dysplasia to carcinoma makes cervical cancer easily preventable disease and provides the rational for screening⁶.

Worldwide successful cervical cancer prevention is based on cytology based screening program i.e. Pap's screening. Unfortunately, the majority of women

in developing countries do not have access to cervical cancer prevention programs. Because a generalized screening program is difficult to implement in developing countries where resources are limited. Not only that, Pap's screening itself has several limitations. These include low sensitivity, a need for trained personnel, laboratory facilities, and patients' compliance with follow-up. The consequence is that, often-cervical cancer is not detected until it is too late to be cured; hence, the risk of death from cervical cancer remains largely uncontrolled.

Thus, alternative strategies are being investigated One alternative strategy is screening by visual inspection of the cervix after application of acetic acid (VIA). The application of a 3—5% solution of acetic acid to the cervix causes cervical intraepithelial lesions to become white. This acetowhitening, which is visible to the naked eye, constitutes a positive result to the VIA test. Initial studies have shown that this method has met the basic criteria of good screening, can give immediate feedback of the test result and importantly, treatment can be provided immediately in the same visit and also VIA sensitivity to be similar to or higher than that of the Pap smear. From this review, many studies described the performance of VIA provided by a variety of health professionals ranging from nonmedical to highly trained medical care professionals practicing in both primary care and referral setting. However, more studies are required to confirm the utility of VIA as a primary screening method.

1.1 Cervical cancer:

Cervical cancer is a malignant neoplasm of the cervix uteri, the lower narrow part of the uterus (womb). The uterus is the hollow, pear shaped organ, where a baby grows during a woman's pregnancy. The upper two thirds of the uterus is

The body or corpus and the lower third comprises the cervix. (Fig 1.1)

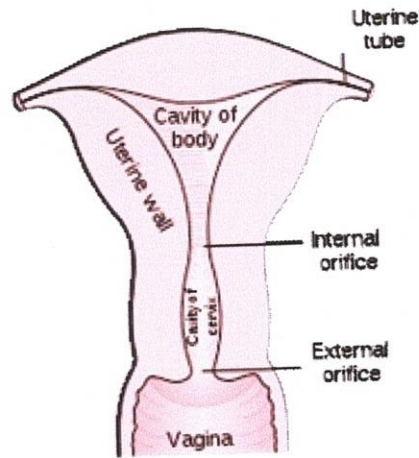


Fig.1.1: Cervix in relation to upper part of vagina and lower part of the body of uterus.

The cervix forms a canal that opens into the vagina (birth canal). External os is the opening of the cervix into the vagina. The portion proximal to the external os is called the endocervix and the portion of the cervix lying exterior to the external os is called the ectocervix. This is the portion of the cervix that is readily visible on speculum examination. The size and shape of the cervix varies widely with age, parity and hormonal influence of the body.

The surface of the cervix is lined by two types of epithelium: squamous epithelium and columnar epithelium. The stratified squamous epithelium is a multilayered epithelium (15-20 layers). It normally covers most of the ectocervix and vagina and in pre-menopausal women, appears pale pink and opaque. In postmenopausal women, the squamous epithelium has fewer layers of cells, appears whitish pink and is prone to trauma, which is often visible as small hemorrhages or petechiae.

A single layer of columnar epithelium lines the cervical canal and extends outwards to a variable portion of the ectocervix. When seen with an endo-

cervical speculum, it appears shiny red. The junction of the squamous epithelium covering the ecto cervix and the columnar epithelium of the endocervix is normally situated at the external os.⁷⁻⁹

The border between the stratified squamous epithelium of the ectocervix and the columnar epithelium of the endocervix is called squamo columnar junction (SCJ). The location of SCJ in relation to the external os is variable. When exposed to the acidic environment of the vagina, the columnar epithelium is gradually replaced by stratified squamous epithelium. This normal replacement process is termed squamous metaplasia and gives rise to a new squamo-columnar junction.¹⁰ The continuous remodeling process is influenced by women's age, hormonal status, birth trauma, infection, oral contraceptive pill (OCP) and certain physiological conditions like pregnancy.¹⁴ These factors stimulate to replace the columnar cells gradually by the squamous metaplastic cells and gives rise to a new SCJ. The area between the original SCJ and newly formed SCJ is known as the transformation zone (TZ). With the onset of menopause, the cervix shrinks due to lack of estrogen and the new SCJ moves towards the external os and into the endocervical canal. In postmenopausal women, the new SCJ is frequently invisible on visual examination.¹¹

Examination of transformation zone is of great importance because approximately 95% of the cervical squamous cell carcinoma occurs in this zone¹¹. If extra nuclear material is provided either from the head of the spermatozoa or from Human Papillomavirus, they act as a mutagen causing chromosomal abnormality and atypical epithelial activity and thereby development of cancer.¹²⁻¹⁴

Most cervical cancers are squamous cell carcinomas, arising in the squamous epithelial cells that line the cervix. Adenocarcinoma, arising in glandular epithelial cells is the second most common type. Very rarely, cancer can arise in

other types of cells in the cervix ¹⁵.

Although cervical cancer can occur at any age, there are two peaks – one at about 35 years and another in their fifth or sixth decade, with a mean age of 54 years at diagnosis. By contrast, the precursor of invasive cervical cancer, cervical intraepithelial neoplasia, usually occurs in women under the age of 40.

1.1.1 Natural history of CIN and cervical cancer:

Cervical cancer is usually preceded by a long phase of cytological changes known as **Cervical Intraepithelial Neoplasia (CIN)**. CIN, also known as cervical dysplasia is potentially premalignant transformation and abnormal growth (dysplasia) of squamous cells lining on the surface of the cervix.²¹ Most cases of CIN remain stable, or are eliminated by the host's immune system without intervention. However a small percentage of cases progress to become cervical cancer, usually cervical squamous cell carcinoma if left untreated.^{16,17} Sometimes a screening test may find changes in the glandular cells that line the cervical canal. Changes to these cells seem to go through the same stages as CIN, are called cervical glandular intra-epithelial neoplasia. If left untreated these changes may develop into a type of cancer known as adenocarcinoma.

CIN is predominantly a disease of younger women, usually develops between 25 to 35 years (The mean age about 30 years), about 15 years less than that of invasive carcinoma, if left untreated.¹⁸

The major cause of CIN is chronic infection of the cervix with the sexually transmitted Human Papilloma Virus (HPV); especially the high-risk HPV types 16 and 18. Over 100 types of HPV have been identified. About a dozen of these types appear to cause cervical dysplasia and may lead to the development of

cervical cancer. Other types cause genital warts.¹⁹

Most of the cervical carcinomas arise at the junction between the primarily columnar epithelium of the endocervix and the squamous epithelium of the ectocervix. This junction is a site of continuous metaplastic change; this change is most active in utero, at puberty, and during first pregnancy and declines after menopause. The greatest risk of neoplastic transformation coincides with periods of greatest metaplastic activity. Virally induced atypical squamous metaplasia developing in this region can progress to high-grade squamous intra-epithelial lesions.²⁰

HPVs infect immature basal cells of squamous epithelium in areas of epithelial breaks or immature metaplastic squamous cells present at squamo-columnar junction. HPVs can not infect mature superficial squamous epithelium; that cover the ectocervix, vagina, or vulva. Establishing HPV infection in these sites requires damage to the surface epithelium, which gives the virus access to the immature cells in the basal layer of epithelium. The cervix, with its relatively large areas of immature metaplastic squamous epithelium, is particularly vulnerable to HPV infection. Although the virus can infect only the immature squamous cells, replication of HPV occurs in maturing metaplastic cells and results in a cytopathic effect, 'koilocytic atypia', consisting of nuclear atypia and a cytoplasmic perinuclear halo. To replicate, HPV has to induce DNA synthesis in the host cells. HPVs activate the mitotic cycle in maturing, non-proliferating squamous cells by interfering with the function of RB and P⁵³, two important tumor suppressor genes.²¹

Mechanism of development of cervical cancer by HPV: Human papilloma viruses, members of the Papovavirus family, are non enveloped with double-stranded circular DNA and icosahedral nucleocapsid. Two of the early genes,

E6 and E7, are implicated in carcinogenesis. They encode proteins that inactivate proteins encoded by tumor suppressor genes in human cells e.g., the p53 gene and retinoblastoma (RB) gene respectively. Inactivation of the p53 and RB proteins is an important step in the process by which normal cells are transformed into cancer cells.²²

E6 induces rapid degradation of P⁵³ level two-three fold via ubiquitin-dependent proteolysis. E7 complexes with hypophosphorylated (active) form of RB, promoting its proteolysis via proteosome pathway. Because hypophosphorylated RB normally inhibits S-phase entry via binding to the E2F transcription factor, the two viral oncogenes cooperate to promote DNA synthesis while interfering P⁵³ mediated growth arrest and apoptosis of genetically altered cells. Thus, the viral oncogenes are critical in extending the life span of epithelial cells-a necessary of tumor development. (Fig 1.2)

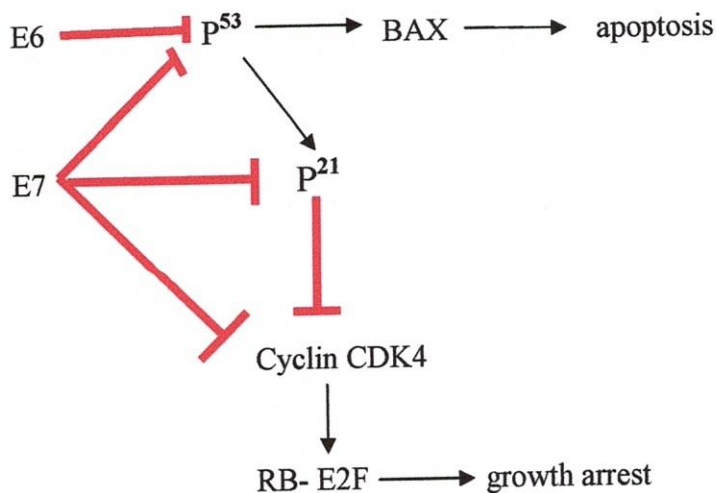
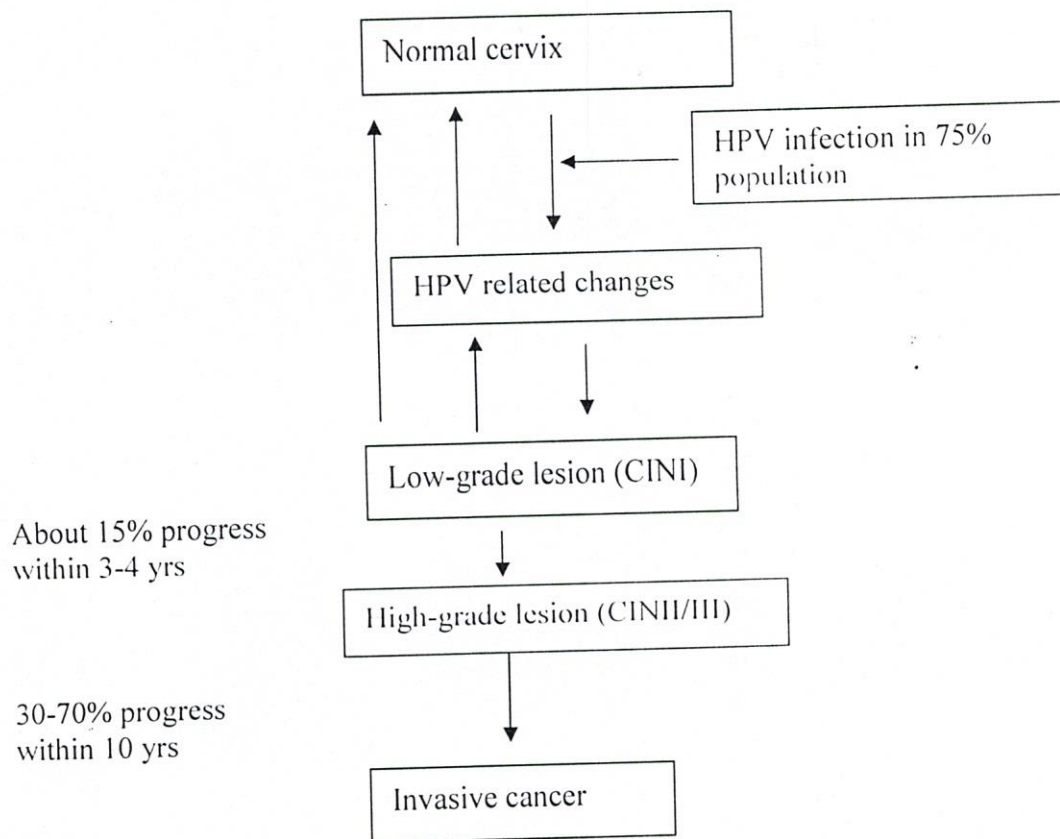


Fig 1.2 Effect of HPV proteins E6 and E7 on the cell cycle.

E6 and E7 enhance P⁵³ degradation, causing a block in apoptosis and decrease activity of the P²¹ cell cycle inhibitor. E7 associates with P²¹ and prevents its inhibition of the cyclin- CDK4 complex; E7 can bind to RB, removing cell cycle restriction. The net effect of HPV E6 and E7 proteins is to block apoptosis and remove the restrains to cell proliferation. (source : modified from Munger K, 2002)²³



Source: (Walboomers J.M, 1999)²⁴

The earliest microscopic change corresponding to CIN is dysplasia (abnormal growth) of the surface lining of the cervix, which is essentially undetectable by the woman. Cellular changes associated with HPV infection, such as koilocytes, are also commonly seen in CIN. CIN is usually discovered by a screening test, the Papanicolaou or "Pap" test or by visual inspection of cervix after application of acetic acid (VIA). An abnormal screening result may lead to a recommendation for colposcopy of the cervix, during which the cervix is examined under magnification.

A screening test can show that CIN is present, but it cannot always show how deeply the abnormal cells go into the cervix. In order to find the grade of

CIN, biopsies are taken from the abnormal areas of the cervix. The biopsies are looked at under a microscope to find the grade of the CIN. This makes it easier for the doctor to decide on the most appropriate type of treatment.

1.1.2 Clinical feature of CIN and cervical cancer

There is no specific symptom or visible sign associated with CIN. Indeed, the affected cervix usually looks remarkably healthy. The disease is therefore discovered either incidentally during the histological examination of cervixes removed for other reasons or during screening procedures. The early stages of cervical cancer may be completely asymptomatic. Clinically, the first symptom may be abnormal vaginal bleeding, usually post coital. Vaginal discomfort, malodorous discharge, and dysuria are not uncommon. In addition, moderate pain during sexual intercourse and a vaginal mass may indicate the presence of malignancy. The tumor grows by extending upward to the endometrial cavity, downward to the vagina, and laterally to the pelvic wall. It can invade the bladder and rectum directly. Symptoms that can evolve, such as constipation, hematuria, fistula, and ureteral obstruction with or without hydronephrosis or hydroureter, reflect local organ involvement. The triad of leg edema, pain, and hydronephrosis suggests pelvic wall involvement.^{25,26}

In advanced disease, metastases may be present in the abdomen, lungs, liver, bones or brain. Symptoms of advanced cervical cancer may include loss of appetite, weight loss, fatigue, pelvic pain, back pain, leg pain and single swollen leg, heavy bleeding from the vagina, leaking of urine or faeces from the vagina and bone fractures. Leg edema suggests lymphatic/vascular obstruction from tumor. If the disease involves the liver, hepatomegaly may develop. Pulmonary metastasis usually is difficult to detect upon physical examination unless pleural

effusion or bronchial obstruction becomes apparent.

The lifetime recurrence rate of CIN is about 20%, but it is not clear what proportion of these cases are new infections rather than recurrences of the original infection.²⁷

1.1.3 Aetiology of CIN and cervical cancer:

In the 1960s Gynaecologists, Pathologists and researchers exerted considerable effort to understand the aetiology of cervical cancer with the help of colposcope. However, studies revealed that persistent or chronic infection with one or more of the so-called high risk or oncogenic types of Human Papilloma Virus (16, 18) is the major risk factor for development of CIN or invasive cervical cancer . HPV viral DNA has been detected in more than 90% of squamous intraepithelial lesions (SILs) and invasive cervical cancers compared with a consistently lower percentage in controls. Both animal data and molecular biologic evidence confirm the malignant transformation potential of papilloma virus-induced lesions.²⁸ The key determinates of HPV infection for both men and women are related to sexual behavior and include early age of first coitus (before age 18), giving birth before age 16, more than one marriage, multiple sexual partners, having sex with an infected partner, having other illnesses or using medications that suppress the immune system and smoking.²⁹⁻³³ Infection of female genital tract by Human Papillomavirus (HPV) generally occurs in their teens, twenties or thirties with a peak prevalence as high as 25-30% under 25 years of age.³⁴

Most HPV infections of cervix resolve spontaneously within a few months. In some cases, persistence of infection occurs and cytological changes take place which progress to CIN or invasive squamous cell carcinoma. So HPV-DNA

testing often recommended for use in women aged 30 years and older. Those who are positive subsequently are assessed for precancerous or cancer lesions and are treated as indicated. Progression through different grades of CIN or carcinoma in-situ or invasive cervical cancer may take several years probably on average more than 15 years suggesting slow progression of the disease.

Though infection with a high risk HPV is the underlying cause of cervical cancer, not all women infected with HPV develop cancer. Most cervical HPV infections regardless of type are short lived, only a small number persist and progress to precancerous lesions or invasive cancer.³⁵ The conditions or cofactors that lead to HPV infection to persist and progress to cancer are not well understood, but the following factors probably play a role:

Age: Cervical cancer is rare in women under 30 years of age and most common over 40 years, with the greatest number of deaths usually occurring in women in their 50s and 60s. CIN are found predominantly in younger women; while invasive cancers are detected more often in women 10-15 years later. These findings indicate that during development of a screening program, priority to women of 35-40 years at the initial stage of the program may help in identifying more cases of CIN within a shorter period.

Early sexual intercourse: Early epidemiology studies in different countries of the world concluded that marriage at early age is the greatest risk factor for development of premalignant cervical abnormalities among women attending tertiary care hospitals. Because metaplastic process is very active in the transformation zone of the cervix at the time of menarche, during and after first pregnancy. These periods are high estrogenic phase, which is an important

trigger for the metaplastic process. These metaplastic cells have the potentiality to undergo atypical transformation by trauma or infection. The prolonged effect of carcinogens can produce continuous changes in the immature cells, which may lead to malignancy.³²⁻³⁵

Social factor: The lower income group and low educational level are important factors in the development of cervical cancer. Because they may be related to higher incidence of early marriage, high parity, low attendance to gynecological clinic and less opportunity of screening.^{36,37}

Co-infection with other sexually transmitted diseases (STDs): such as Herpes Simplex Virus (HSV) type 2, Chlamydia tracomatis, and Neisseria gonorrhoea. Women with past or recent infection are at greater risk of developing cervical cancer than women who have never had STDs.^{30,33}

Oral pill users: Several studies have reported a strong association between cervical cancer and long term use of oral contraceptive pills (OCPs). Women who have taken OCPs for more than 10 years have a much higher risk of HPV infection (up to four times higher) than those who do not use OCP.^{47,48} The reasons for this risk are not entirely clear. Some experts suggest that hormones in the pill stimulate new cell formation in the cervix and these immature cells are vulnerable to trauma or viral infection like Human Papilloma Virus (HPV) and Herpes Simplex Virus (HSV).^{37,38}

Smoking habit: Nicotine itself is carcinogenic which may damage the immune system of the body. Cigarette smokers are also deficient in folate which may play role in development of dysplasia.^{30,37,38}

Exposure to Diethylstilbestrol (DES): It is an estrogen compound, was used previously by pregnant women in the 1940s and 1950s. The daughter of these women faces a higher risk of development of cervical cancer.^{11,12}

Immuno suppressed individual such as human immune deficiency virus (HIV) infection: HIV is the Virus that causes AIDS (Acquired immune deficiency syndrome). Women with HIV have compromised immune system and therefore are more likely to contract HPV, which may lead to cervical cancer. Immune system plays a vital role in eliminating and slowing the progression of cancer cells. Therefore, cervical cancer in patients with HIV may become invasive more quickly than in patients with healthy immune function.³⁹

1.1.4 Management of CIN:

The clinical management of CIN I may take one of the following courses:

- (i) Follow up and counseling. If the lesion is persistent or progressive after 18 to 24 months then treatment is offered.
- (ii) Immediate treatment at first colposcopy visit, based on colposcopic findings, to maximize treatment coverage (Our national policy follow this rule).

CIN II and III need treatment and follow up. Types of surgery for high-grade lesions include⁴⁰⁻⁴¹

- Loop electrosurgical excision procedure (LEEP) -- uses electricity to remove abnormal tissue
- Cryotherapy -- freezes abnormal cells
- Laser therapy -- uses light to burn abnormal tissue

Women treated with CIN reviewed at 9- 12 months after treatment.

1.1.5 Appearance of CIN and preclinical invasive carcinoma on VIA:

Application of acetic acid is believed to cause a reversible coagulation or precipitation of the cellular proteins and cytokeratins. Thus, the effect of acetic acid depends upon the amount of cellular proteins and cytokeratins present in the epithelium. Areas of CIN undergo maximal coagulation due to their higher content of nuclear proteins and prevent light from passing through the epithelium. As a result, the sub epithelial vessel pattern is obliterated and the epithelium appears white.

CIN-I: After application of acetic acid, shiny white lesions appear which has flat surface, indistinct or hazy borders. Acetowhite changes occur slowly lasts for a short time and fades quickly.⁵² (Fig 1.3)

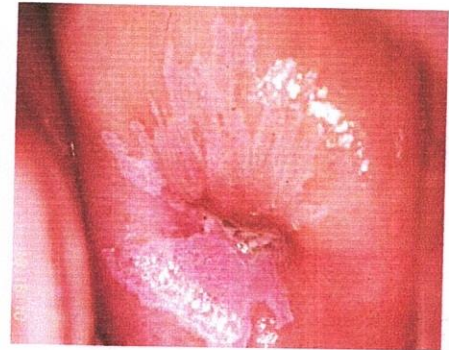

Fig 1.3: Thin acetowhite lesion with Irregular margin arising from SCJ, suspicious of CIN I

CIN- II: After acetic acid application, white lesion, which appear as flat surface but sharp and distinct margins. Lesions appear quickly, last for several minutes and fade slowly and are iodine negative.⁵² ((Fig 1.4)

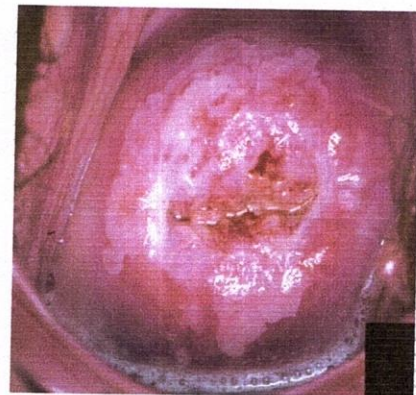


Fig 1.4: A moderately dense acetowhite area, with regular margin, suspicious of CIN-II

CIN-III: After application of acetic acid, lesions appear very quickly, stay for longer and fade slowly. Lesions are ivory or oyster white in color with round or may be uneven surface and have very sharp raised margins. CIN lesions do not contain glycogen and thus do not stain iodine and remain mustard or saffron yellow area. (Fig 1.5)

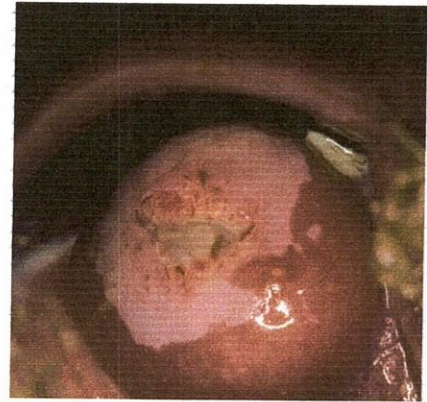


Fig 1.5: A cervicoforniceal dense acetowhite area, suspicious of CIN-III

Invasive lesion: After application of acetic acid, intense acetowhite epithelium along with vascular abnormalities may be seen. The surface contour is irregular, hyperaemic, bleeds on touch and breach on mucosal integrity may be there. Appearance of atypical blood vessels may indicate the first sign of invasion. (Fig 1.6)

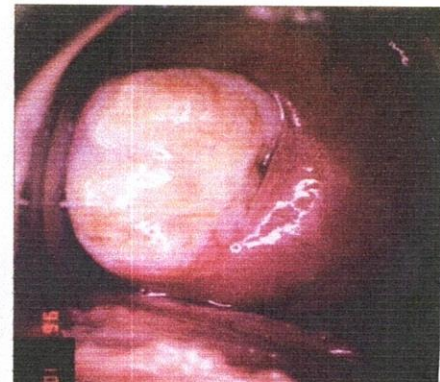


Fig 1.6: Dense, acetowhite lesion with raised margin and irregular, nodular surface suggestive of early invasive carcinoma

1.1.6 Colposcopic appearance of CIN and preclinical invasive carcinoma:

The colposcopic diagnosis of cervical neoplasia depends on the recognition of four main features: Intensity (color tone) of acetowhitening, margins and surface contour of acetowhite areas, vascular features and color changes after iodine application.^{41,42}

CIN-I: After saline application, cervix usually does not show any abnormality but sometimes foci of fine and regularly placed punctations and hyperaemic areas may be seen.

After application of acetic acid, shiny white lesions appear which has flat surface, indistinct or hazy borders. Acetowhite changes occur slowly lasts for a short time and fades quickly. Vascular pattern is either inconspicuous or may show fine and regular mosaic and punctation. Such patterns are also seen with metaplastic epithelium, sub clinical papilloma infection or regenerative epithelium. (Fig 1.7)

CIN- II: After saline application, coarse punctations or localized hyperaemia may be seen. After acetic acid application, white lesion, which appear as flat surface but sharp and distinct margins. Lesions appear quickly, last for several minutes, fade slowly, and are iodine negative. Coarse punctations and mosaic may be seen but intercapillary distance usually remains normal.((Fig 1.8)

CIN-III: After saline application, coarse and irregularly placed punctations, local hyperaemia may be seen.

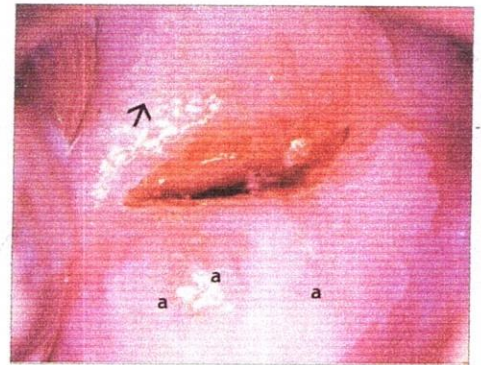


Fig 1.7: Mild to dense acetowhite lesion with fine mosaic. histology indicated CIN I

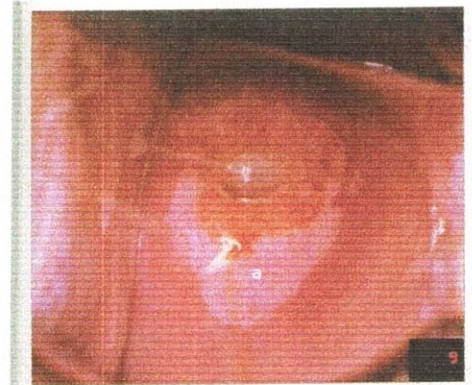


Fig 1.8: Dense acetowhite lesion with varying regular colour intensity and coarse mosaics (a) in a CIN II lesion.

After application of acetic acid, lesions appear very quickly, stay for longer and fade slowly.

Lesions are ivory or oyster white in color with round or may be uneven surface and have very sharp raised margins. Vascular pattern is abnormal in the form of coarse and irregular mosaic or punctation. Intercapillary distance is markedly increased. (Fig 1.9)

CIN lesions do not contain glycogen and thus do not stain iodine and remain mustard or saffron yellow areas.

Invasive lesion: After saline application, the surface contour is irregular, hyperaemic, bleeds on touch and breach on mucosal integrity may be there.

After application of acetic acid, intense aceto white epithelium along with vascular abnormalities may be seen. (Fig 1.10)

Appearance of atypical blood vessels may indicate the first sign of invasion. There may horizontal superficial vessels running parallel to the surface having irregular course with shape, irregular bends, may show constrictions and dilatation and may appear or disappear abruptly. Vessels are usually placed at a greater distance than normal. When atypical vessels make its

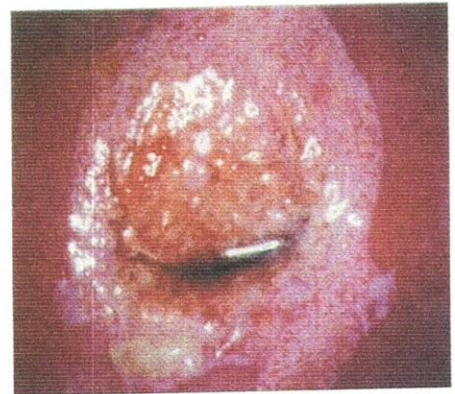

Fig 1.9: Dense acetowhite lesion with regular margin and coarse, irregular punctation in a CIN III lesion.

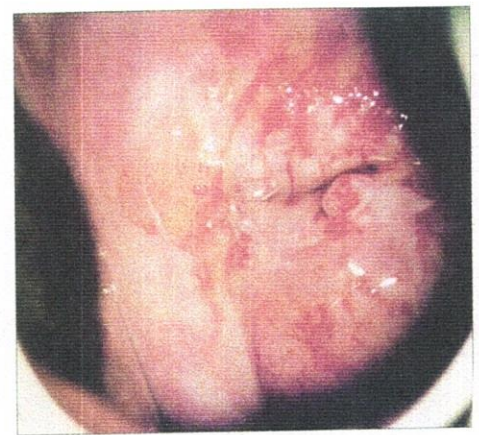

Fig 1.10: Invasive cervical cancer: irregular surface with atypical blood vessels in the dense acetowhite area.

appearance in an extensive area in CIN lesion, it indicates early invasion. Vascular atypia is more common in well-differentiated squamous cell carcinoma than poorly differentiated lesions. (Fig 1.10)

1.1.7 Histopathological Findings of CIN and cervical carcinoma:

Low grade squamous intraepithelial neoplasia (LSIL) or CIN I :

If abnormal cell growth confined to the basal 1/3 of the cervical epithelium, the lesion is designated as CIN I or LSIL.²⁸ Mitotic figures are present, but not very numerous. Cytopathic changes due to HPV infection may be observed in the full thickness of the epithelium and typically cleared by immune response in a year or so. If left untreated, about 70% of CIN-1 will regress within one year, and 90% will regress within two years. Only about 1% of untreated CIN-I can progress to severe dysplasia.^{22,42} (Fig 1.11)

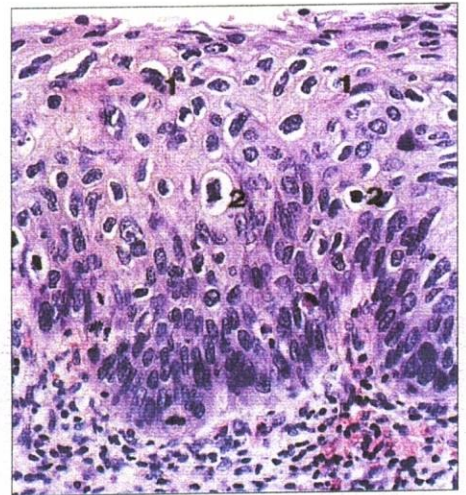


Fig 1.11: CIN I

High grade squamous intraepithelial neoplasia (HSIL) or CIN II and CIN III:

CIN II: If dysplasia confined to the basal 2/3 of the epithelium, the lesion is designated as CIN II or HSIL.²⁸ Nuclear

abnormalities are more marked than CIN I. Mitotic figures are present throughout the lower half of the epithelium. About 50% of CIN II will regress within 2 years without treatment. 16% will progress to the next stage in 2 years and 25% will progress after 5 years. Progression to cancer typically takes 15 (3 to 40) years.^{22,42} (Fig 1.12)

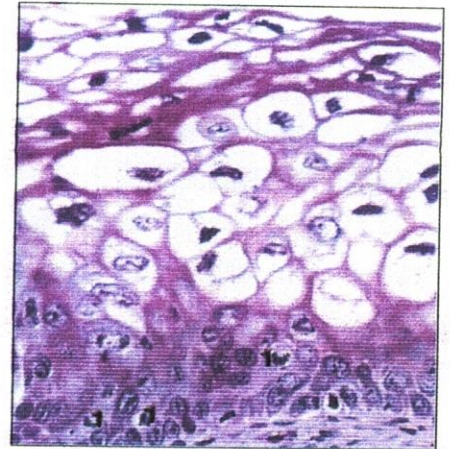


Fig 1.12: CIN II

CIN III / carcinoma-in-situ: If dysplasia spans more than 2/3 of the epithelium or involve the full thickness the lesion is designated as CIN III or carcinoma-in-situ. Numerous mitotic figures and marked nuclear abnormalities extend throughout the lower half of the epithelium. This lesion may sometimes also be referred to as cervical carcinoma in situ. The neoplastic cells do not invade the basement membrane.^{22,42} (Fig 1.13)

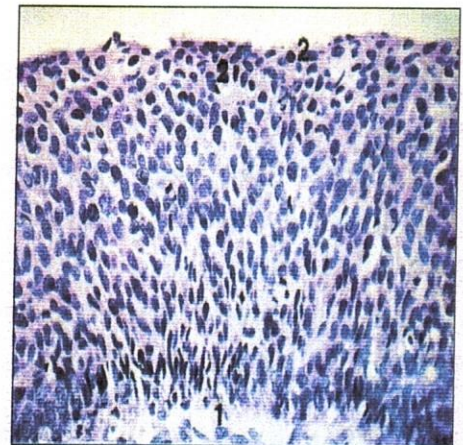


Fig 1.13: CIN III/ ca- in situ

Depending upon the degree of neoplastic changes and or its invasion to the adjacent stroma the lesions are diagnosed as microinvasive and invasive forms. Microinvasive carcinoma is one which is predominantly intraepithelial carcinoma, except that there is disruption of the basement membrane. The neoplastic epithelium invades the stroma in one or more places but limited up to

5 mm from the overlying basement membrane. (Fig 1.14) The malignant cells maintain their connection with the overlying intraepithelial neoplasm. The cords of malignant cells may become confluent or invade the lympho-vascular channels, irrespective of depth of penetration^{16,17}

In invasive carcinoma, the invasion of the malignant cells to the underlying stroma exceeds 5 mm. (Fig 1.15)

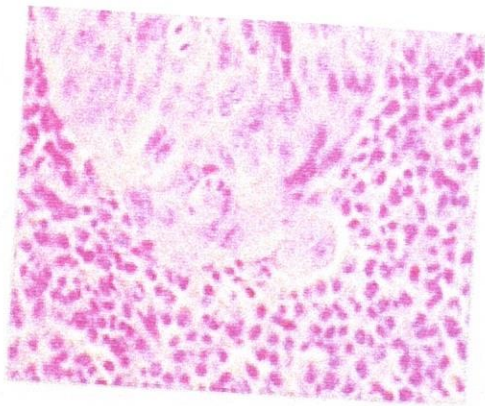


Fig 1.14: Microinvasive carcinoma (x 40)

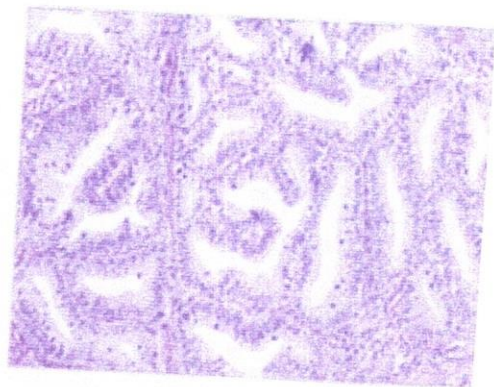


Fig 1.15: Invasive carcinoma (x 20)

Some invasive cancers of the cervix are hypertrophic or exophytic, producing cauliflower like mass, (Fig 1.16) others are mainly eroding and ulcerative or infiltrative.^{5,9} (Fig 1.17)

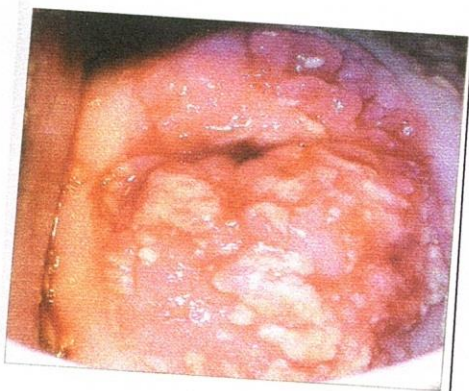


Fig 1.16: Invasive cancer: hypertrophic growth on the cervix

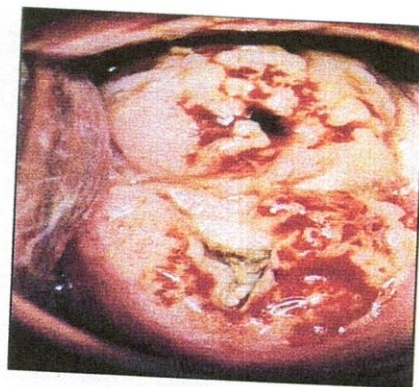


Fig 1.17: Invasive cancer: ulcerated fungating growth on the cervix

1.1.8 Pap smear cytological findings of CIN and cervical carcinoma:

CIN may be identified by microscopic examination of cervical cells in a cytology smear stained by the Papanicolaou stain. In cytological preparations, individual cell changes are assessed for the diagnosis of CIN and its grading.

Cytology of CIN: Disproportionate nuclear enlargement, nuclear hyperchromasia (increased intensity of staining), irregularity of the nuclear membrane, irregular chromatin distribution with clumping is always present in the dysplastic cells. Abnormal nuclei in the superficial or intermediate cells indicate a low-grade CIN, whereas abnormality in nuclei of parabasal and basal cells indicate a high-grade CIN. The amount of cytoplasm in relation to the size of the nucleus (nuclear- cytoplasmic ratio) is one of the most important bases of assessing the grade of CIN. Increased ratios are associated with more severe degrees of CIN. (Fig 1.18, 1.19) More often, a cervical smear contains cells with a range of changes; considerable challenges and subjectivity; therefore, experience of the cytologist is critically important for final reporting.^{41,42}

Cytology of microinvasive and invasive carcinoma: Smears usually show very large numbers of dyskaryotic cells, variation in size and shape of cell nuclei, often including very small cells, hyperchromasia with coarse aggregation of nuclear chromatin, tissue fragments of small severely dyskaryotic cells, including fibre cells and tadpole shaped cells. (Smear background containing necrotic debris, leucocytes and blood described as tumor diathesis.^{11,12,42} (Fig 1.18, 1.19)

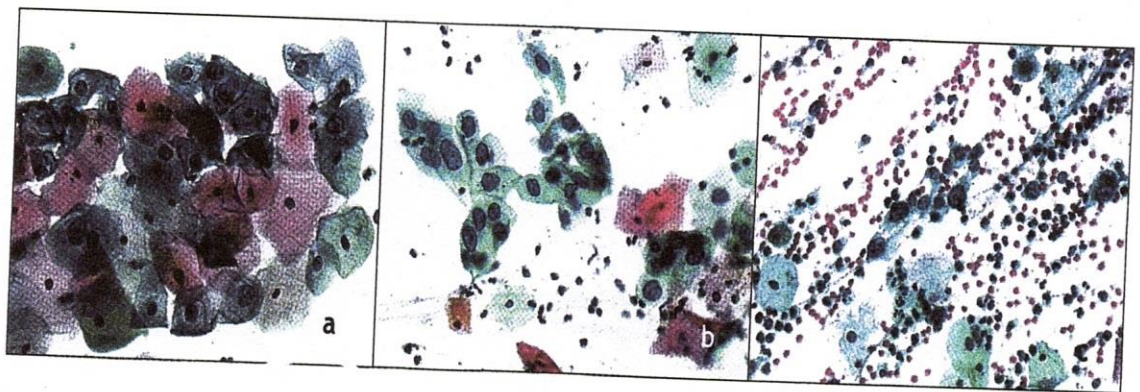


Fig. 1.18: cytological appearance of and CIN I (a), II (b) and III(c)

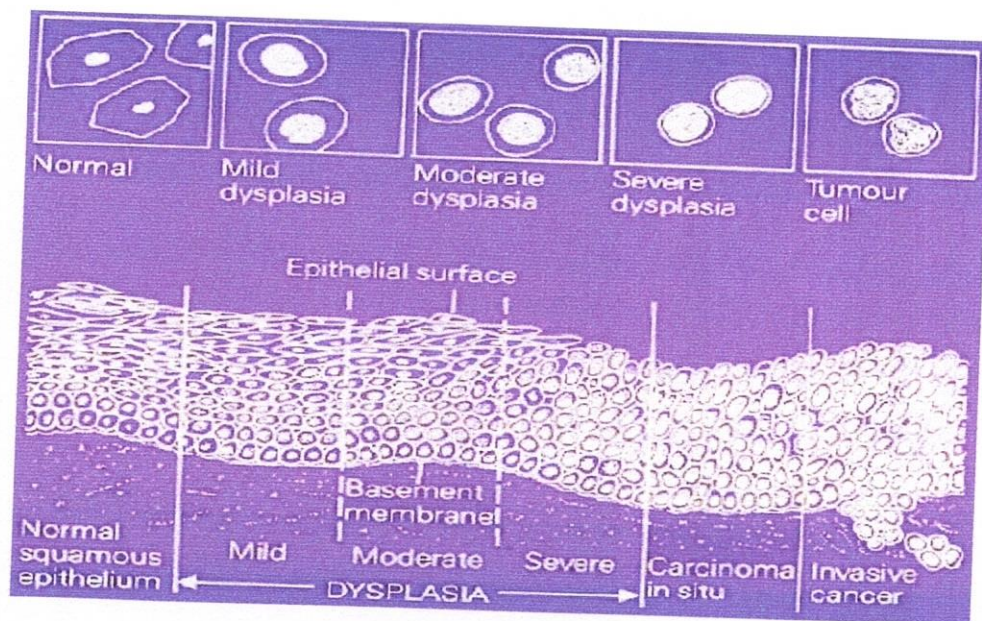


Fig. 1.19: Diagrammatic figure of cytology and histology of CIN and invasive cancer

1.2 Prevention of cervical cancer:

1.2.1 Primary prevention:

Cervical cancer can be prevented primarily by educating the general population about the risk factors of cervical cancer and their prevention (e.g.

delaying first intercourse, reducing number of sexual partners, stopping smoking, using condoms etc), by creating mass awareness about pre invasive and invasive course of cervical cancer, undertaking family planning related health education programs etc., by using of barrier contraceptives (condoms) and administration of vaccines against HPV. The vaccine is approved for girls and women ages 9-26, because the vaccine only works if given before they become sexually active. Research suggests that the vaccine may also help to prevent vaginal and vulval cancers.⁴³⁻⁵²

1.2.2 Secondary prevention by screening:

Screening of a cancer is the application of a test to detect a potential cancer in a person who has no sign or symptom of the disease. It is not undertaken to diagnose a disease but to identify individuals with a high probability of having or of developing the disease. It is a secondary form of cancer prevention, which involves identifying by screening and treating the disease earlier in the more treatable stage.

1.2.3 Guidelines for cervical cancer screening

A Pap smear is a routine laboratory diagnostic test used by American College of Obstetrics and Gynecologists (ACOG) to detect cell changes in a woman's cervix that might indicate a precancerous or cancerous condition. Until 2003, when ACOG⁵³ revised its original guidelines for cervical cancer screening, it was recommended that women will receive a pap test yearly, during their annual pelvic exam, from age 18 on. The guidelines were changed to eliminate unnecessary testing of younger and older women with no history of abnormal pap smears and low risk of developing cervical cancer.

Under Age 21: If a younger girl is sexually active, ACOG recommends a pelvic exam and Pap smear along with routine testing for sexually transmitted diseases (STDs) within three years following first intercourse. STD testing includes screening for Chlamydia, gonorrhea and Human Immunodeficiency Virus (HIV).

Age 21 to 30: ACOG guidelines recommend that pelvic examinations with pap smears should begin at age 21. Thereafter, annual screening should continue up to age 30. Women in this age group have a higher risk than older women of contracting Human Papilloma Virus (HPV).

Age over 30 to 65: From age 30 on, ACOG guidelines says that screening can be cut back to every two or three years whenever a woman has three consecutive test results that were normal, has no conditions that affect the immune system, was not exposed to the drug Diethylstilbestrol (DES) while in utero (before birth), and has no other medical problems that require annual or semi-annual examinations. Routine physical pelvic exams should continue annually.

Age over 65: Although routine pelvic exams should continue after age 65, ACOG guidelines say that, under certain conditions, Pap smears can be discontinued at this point. If a woman has three consecutive Pap smears that are normal and had no abnormal results during the previous 10 years, has no history of cervical cancer, HIV or other conditions that affect the immune system, is not at risk of acquiring STDs and was not exposed to Diethylstibesteron (DES), Pap smears can be eliminated from the annual exam.

Exceptions: If a woman of any age has a complete hysterectomy for reasons

other than cancer and has never had abnormal pap smears, pap testing may be eliminated from routine pelvic exams.

1.2.4 Methods of cervical cancer screening:

Following methods are used for screening of cervical cancer:

- a) Cytology based screening (Pap smear)
- b) Visual inspection of cervix after application of acetic acid (VIA) or lugol's Iodine (VILI) based screening
- c) Colposcopy
- d) Human papilloma virus (HPV) DNA based screening
- e) Others: Liquid based cytology (LBC), Cervicography, Fluorescence spectroscopy, down staging.

1.2.4(a) Cytology based screening (Pap smear):

The broadest and most successful application of clinical cytology has been in the diagnosis of invasive carcinoma of the uterine cervix and precursor lesions through the technique popularized by George Papanicolaou at Cornell University and universally known as Pap test.⁵⁴ Pap smear techniques relies on a microscopic examination of cervical cells collected from squamocolumnar junction or posterior vaginal pool during the cervical smear procedure. This method allows detection of cellular changes indicating the possible genesis of cervical cancer. The accuracy of cytological test depends on the quality of the services including sampling practices, preparation and interpretation of smears in the laboratory. In the developed countries, conventional cytology can detect up to 84% of precancer and cancer. The specificity of the test is usually over 90 %.⁵⁵⁻⁶¹

1.2.4(b) Visual Inspection of cervix with acetic acid (VIA) based screening :

VIA involves swabbing the cervix with 3-5% freshly prepared acetic acid solution and examination of the cervix in good light. When exposed to this solution for a minute, abnormal cells temporary turn white and reveal acetowhite epithelium of the transitional zone allowing the provider to make an immediate assessment of a positive or negative result. Application of acetic acid is believed to cause a reversible coagulation or precipitation of the cellular proteins. It also causes swelling of the epithelial tissue, dehydration of the cells and also helps in coagulating and clearing the mucous secretions on the cervix. If the epithelium contains a lot of cellular proteins, acetic acid coagulates these proteins, which may obliterate the color of the stroma.⁴¹ The resulting acetowhitening is seen distinctly as compared with the normal pinkish color of the surrounding normal squamous epithelium of the cervix.⁴¹ In research settings, VIA has been shown to have an average sensitivity for detection of pre-cancer and cancer of almost 77% and specificity 86%.⁶²⁻⁷⁰ It is considered to be a feasible method for screening of cervical cancer in the present socioeconomic context of Bangladesh as it fulfills all the criteria of an ideal screening method.

Reporting of visual inspection findings

VIA negative: VIA screening is reported as negative in the case of any of the following observations: ^{41,42}

- No acetowhite lesions are observed on the cervix. (Fig 1.20)
- Polyps protrude from the cervix with bluish-white acetowhite areas.
- Nabothian cysts appear as button-like areas as whitish acne or pimples.

- Dot-like areas are present in the endocervix, which are due to grape-like columnar epithelium staining with acetic acid.
- Shiny, pinkish-white, cloudy-white, bluish-white, faint patchy or doubtful lesions with ill defined margins.
- Angular, irregular, digitating acetowhite lesions resembling geographical regions distant from the squamocolumnar junction (satellite lesions).
- Streak like acetowhitening in the columnar epithelium.
- Ill-defined, patchy, pale, discontinuous, scattered acetowhite areas.

VIA positive: The VIA test outcome is reported as positive in any of the following observations:^{41,42}

- Distinct, well-defined, dense (opaque, dull or oyster-white) acetowhite areas with irregular or irregular margins, close to or abutting the squamocolumnar junction or in the transformation zone or close to the external os if the squamocolumnar junction is not visible. (Fig 1.21)
- Strikingly dense acetowhite areas are seen in the columnar epithelium.
- The entire cervix becomes densely white.
- Condyloma and leukoplakia occur close to the squamocolumnar junction, turning intensely white after application acetic acid.
- The test outcome is scored as invasive cancer when there is a clinically visible ulcero-proliferative growth on the cervix that turns densely white after application of acetic acid and bleeds on touch.

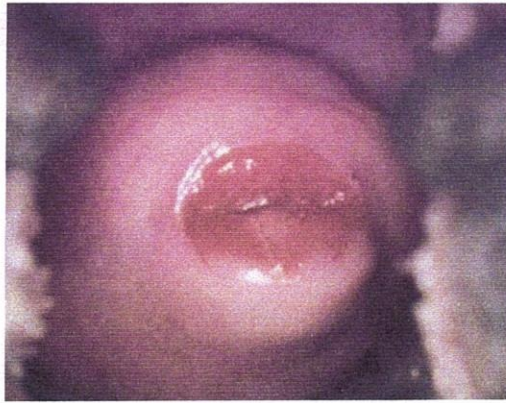

Fig 1.20: VIA negative (No acetowhite lesion on the cervix)

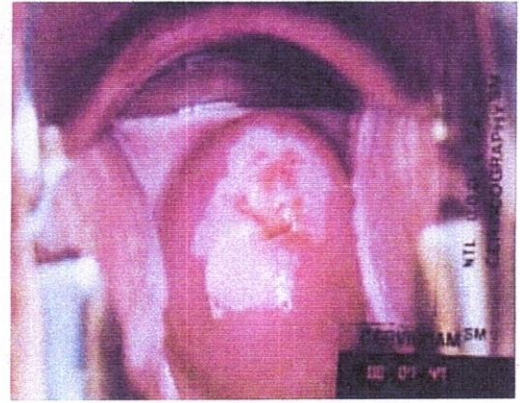
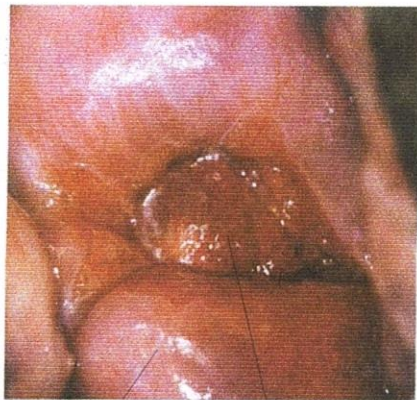


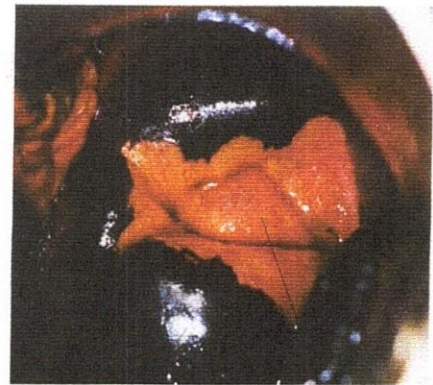
Fig 1.21: VIA positive (acetowhite lesion on the cervix in SCJ)

Visual Inspection of cervix with Lugol's iodine (VILI) based screening or Schiller test:

Normal squamous (both original and mature metaplastic) epithelial cell contain stores of glycogen that give a mahogany brown or nearly black stain when an iodine containing solution, such as lugol's is applied. In contrast, normal columnar epithelium does not contain glycogen and does not take up the iodine stain. Similarly, immature squamous metaplasia, inflammatory and regenerating epithelium, congenital transformation zone, condylomata either do not or only partially stain with iodine.^{41,42} Iodine staining is useful in distinguishing HPV lesion from significant dysplastic lesions and also very helpful for determining whether vaginal lesions are present.(Fig 1.23) It is important always to integrate the findings of the saline, acetic acid and iodine test to make a colposcopic assessment. Application of iodine clearly delineates the borders of a lesion before a biopsy, or treatment of the lesion is attempted.



Squamous epithelium Columnar epithelium



Squamous epithelium Columnar epithelium has not taken up iodine

Fig 1.22: Before application of Lugol's iodine

Fig 1.23: After application of Lugol's iodine

As VIA and VILI do not rely on laboratory services, they are promising alternatives to cytology where resources are limited. One study showed that the sensitivity of VILI is higher than that of VIA (92%).⁷²⁻⁷⁵ VIA and VILI can be performed in outpatient facilities. They are both short procedures and cause no pain, assessment is immediate and no specimen is required.

1.2.4(c) Colposcopy

Colposcopy is low-power, binocular microscope (magnification 6-16 times) with a powerful light source that allows the physician to view the cellular pattern of surface epithelium of cervix and the surrounding blood vessels after application of saline, acetic acid and Lugol's iodine solution in successive steps. Satisfactory colposcopic examination includes visualization of the original squamocolumnar junction, columnar epithelium and the transformation zone entirely. In fact, colposcopy not only diagnose the cervical lesions but also identifies the site where from biopsies is to be taken.

When used as a diagnostic tool on patients with a positive screen test, colposcopy has a high sensitivity (around 85%) and a specificity of about 70%

for the detection of precancerous and cancer. It is complementary and not a substitute for VIA or cytology.⁷⁶⁻⁷⁸

Morphological basis of Colposcopic Appearances

The colposcopic diagnosis depends upon five basic characteristics.⁷⁹ These are:

1. Vascular pattern;
2. Inter-capillary distance;
3. Surface contour;
4. Color tone relative to the junction of normal and abnormal tissue;
5. Sharp line demarcation between different types of epithelium.

1.2.4(d) HPV DNA based screening:

New screening procedures are based on the detection of high risk HPV DNA in vaginal or cervical smears. HPV testing combined with a cervical cytology smear has been approved as a primary screening approach in the patient age 30 years and older, who still has her uterus and has no immunosuppression. If both results are negative, combined screening should not be repeated for 3 years. If both testing are positive, colposcopy is advocated. If either test is abnormal, repeat both tests in 6-12 months with colposcopy is recommended¹².

The Hybrid Capture II HPV test is a second-generation DNA test that relies on signal amplification to achieve high sensitivity. It is qualitative detection of 18 types of HPV- DNA in the cervical specimen. Specimens containing the target DNA hybridize with a specific HPV RNA probe cocktail.

Specimens are treated with a denaturant to break up cell DNA to form single-stranded DNA. Then HPV-specified RNA probes are added and hybridization allowed proceeding. If there is a specific HPV type in the specimen, its genomic DNA will form an RNA-DNA hybrid. The resultant RNA: DNA hybrids captured onto the surface of a microplate well coated with antibodies specific for RNA: DNA hybrids. Immobilized hybrids are then reacted with

alkaline phosphatase conjugated antibodies specific for RNA: DNA hybrids. Multiple conjugated antibodies bind to each captured hybrid resulting in substantial signal amplification. As the substrate is cleaved by the bound alkaline phosphatase, light is emitted which is measured as relative light units (RLU) on a luminometer. The intensity of the light emitted denotes the presence or absence of target DNA in the specimen. (Fig 1.23)

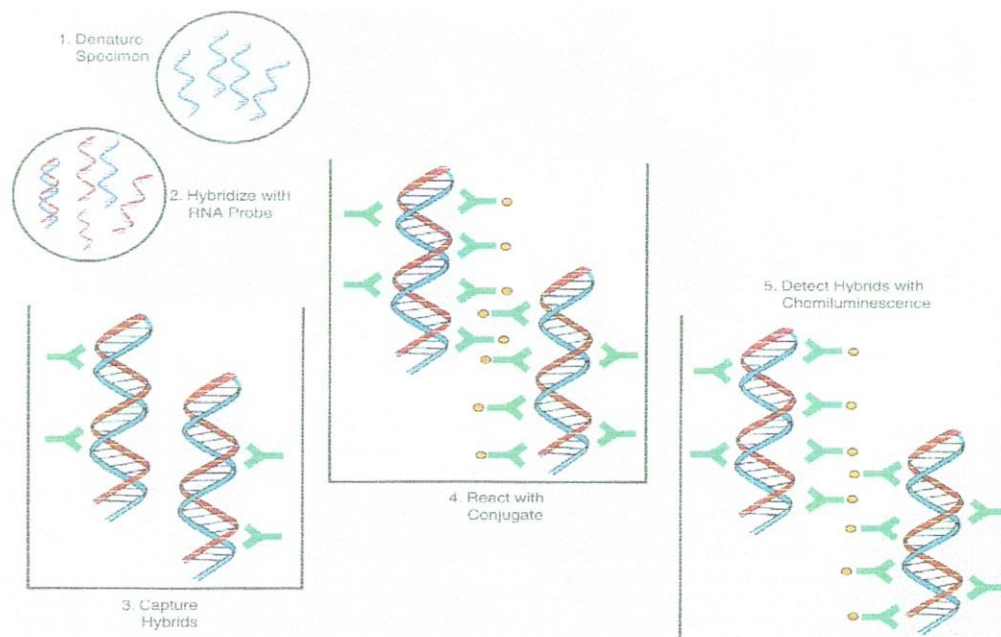


Fig: 1.24 The Hybrid Capture II HPV test

An RLU (relative light unit) measurement equal to or greater than the cut off value indicates the presence of HPV DNA sequence in the specimen. An RLU measurement less than the cut off value indicates the absence of specific HPV DNA sequences tested or HPV DNA levels below the detection limit of the assay (Catalogue no: 5101-1096 IVT 2002 Digene Manufacture). Detection of high risk HPV DNA does not necessarily mean that precancer or cancer is present. It indicates simply that there is a HPV infection. As most HPV infection clears spontaneously in women in their teens and 20s, presence of

HPV in women aged 30 years or older indicates a good chance that the virus has persistent in their system; these women are considered to be at high risk of present or future cervical cancer. Those who are positive subsequently are assessed for precancerous or cancer lesions and are treated as indicated.

Combination of both cytology and HPV test has very high sensitivity and negative predictive value approaching 100%.⁸⁰⁻⁸³ As HPV test is very expensive, it is recommended as an adjunct to the Pap test but not as the sole method of primary screening. If both results are negative, combined screening should not be repeated for 3 years. If both testing are positive, colposcopy is advocated. If either test is abnormal, repeat both tests in 6-12 months with colposcopy is recommended.

The high cost and the need for both a molecular laboratory and reliable methods of transport, and the feasibility of HPV testing has not been demonstrated in low-resource settings. A new, faster, highly sensitive and less costly test for HPV is under development but is not yet available.

1.2.4(e) Other screening tests: are being investigated for use in combination with Pap smear for improving accuracy. For example:

Liquid based cytology (LBC): The refinement of conventional cytology was introduced in the mid 1990s and is increasingly used in high-resource settings. Instead of smearing cervical cells on a slide, the provider transfers the specimen from a brush to a preservative solution. The specimen is sent to a laboratory where the slide is prepared. LBC is more expensive than conventional cytology and laboratory staff needs to be specially trained. However, it appears to have a number of advantages over conventional methods.³

Cervicography: Cervicography is a photographic screening using 33 mm camera. Photographs are taken from the cervix with a specially designed

camera called cervicoscope. Film is developed, projected and is viewed by an expert colposcopist. Similar to colposcopy, cervix is treated with 5% acetic acid before photography. It may prove to be a useful combination to Pap test, particularly in high-risk younger women. It is painless, easy to use, provides documentation of the area and is highly sensitive to abnormal changes. It is also helpful where cytology service is not available.

Fluorescence Spectroscopy: Small non-invasive probes that can be swept across the surface of the cervix to detect cancer. One probe emits a laser light. The head of the probe catches the return signals from the women's cervical cells and compares them with a computer library of cancer cells. In one comparison test, fluorescent spectroscopy was more accurate than Pap smear but not as effective as other screening methods.

Down staging: means the detection of disease in an earlier stage by nurses or other paramedical workers using a simple speculum for visual inspection of the cervix. It is an experimental approach suggested by WHO as an alternative to regular cytologic screening. Compared to cytological screening it is suboptimal. However, in developing countries where effective mass screening cannot be extended and the majority of cases of carcinoma cervix are diagnosed at an advanced stage, 'down staging screening' offers at least an early detection of disease. The strategy is however not expected to lower the incidence of cancer cervix, but it can certainly minimize the cancer death through early detection.

Endocervical curettage: In an endocervical cancer, when portio vaginalis appears apparently healthy and the cervix feels barrel shaped, endocervical curetting is of diagnostic value.

1.3 Review on research work done on Pap smear, VIA and HPV-DNA test

According to history, before the advent of Pap smear and programmatic screening, health care providers relied on looking at the cervix to detect abnormalities. Schiller test had been used to aid in differentiating 'mature' normal to 'immature' abnormal epithelium. After 1950, when the Pap smear became the standard for cervical cancer screening, increasing number of women undergoing this test led to increase utilization of the colposcope (initially developed in 1930) to confirm screening findings. Few years later, due to the expense and inconvenience of colposcopy services, clinicians began to explore whether unmagnified visualization of the cervix (with acetic acid) could be used as an adjunct to cytology, so that patients in need of colposcopy could be identified more effectively and efficiently.

World Health Organization (WHO) supported a study in India between 1988 and 1991 in which unmagnified visual inspection with acetic acid washing was evaluated as a "down staging" technique. VIA was found to be effective identifying women with cancer at an earlier, more treatable stage⁸⁵.

Many studies have been done to compare VIA to Pap smears as a screening method for cervical cancer. Most studies have compared VIA to Pap, looking at sensitivities and specificities of both, while comparing them to colposcopy with biopsy as the gold standard.

In 1982, **Ottaviano** et al.⁸⁴ published an important study involving 2,400 women who were examined visually and colposcopically after a cervical wash with acetic acid. Naked eye (unmagnified) inspection detected abnormalities in 98.4% of the cases (i.e. in 307 of 312 patients assessed colposcopically as having an abnormal transformation zone). These authors concluded, "colposcopically magnification is not essential in clinical practice for the

identification of the cervix at risk.”

Gaffkin⁸⁶ in 2003 published a mini- meta-analysis reviewing the data of what had been published about direct visualization with acetic acid from 1982 to 2002. After finding numerous cites on PubMed, she chose 15 studies from which to review. The 15 studies encompassed over 34,000 women from across the world and the specialists performing the tests ranged from nurses to physicians. The range of estimated VIA sensitivity values from these studies was 66-96% and specificity rates from 64% to 98%. In this study, Gaffkin published test qualities of PAP smears ranging from 11-99%. Gaffkin concluded that VIA was comparable to PAP smears in terms of detecting high-grade lesions or cancer.

In 2001, **Bellinson**⁷³ went to rural China and examined 1,997 women considered to be high risk. In this study they compared visual inspection with acetic acid to colposcopy with biopsy. All exams were performed by gynecologist oncologists and their fellows; the person performing the visual inspection was not the same person performing colposcopy and both examiners were blinded to results. The biopsies included colposcopy directed biopsies if abnormalities seen, one undirected biopsy at 2, 4, 8, or 10 o'clock at the squamocolumnar junction in each normal quadrant, and an endocervical curettage. For biopsy proven CIN II or greater, the sensitivity of VIA was found to be 71% and specificity 74%. The positive predictive value of VIA in this study was found to be 11% and the negative predictive value 98%. Bellinson concluded that the sensitivity of VIA equaled or exceeded reported rates for conventional cervical cytology and encouraged continued research into the possibility of a 'see and treat' method for cervical cancer screening.

Two years later, in 2003, a study was done in the Philippines, a country where there were almost 70,000 cases of cervical cancer, with ~7,000 new cases each year. (Ladines, PGH cancer Institute) **Ngelangel**⁸⁷ compared VIA to two types of PAP smears. 12,992 women between the ages of 25-65 from five different community hospitals throughout the Philippines underwent four different screening exams: VIA, magnified visualization with acetic acid (VIAM), Pap smear with spatula and Pap smear with cervical brush. He based the quality of these four screening tests on colposcopy with biopsy of suspicious lesions as the gold standard. Both nurses and physicians conducted the studies. Sensitivities for the four tests were found to be 37% for VIA, 34.1% for VIAM, 14.3% for spatula PAP, and 19.1% for cervical brush PAP. The specificity rates were 90.7%, 90.7%, 97.5%, and 97.9% respectively. VIA had the highest sensitivity of the four tests. Ngelangel concluded that VIA and VIAM methods are recommended for initial cervical cancer screening in the Philippines.

Ghaemmaghami⁸⁸ tested the VIA method of cervical cancer screening in Iran where cervical cancer is the number one cause of cancer related death in women. 1,200 women between the ages of 18 and 70 from Tehran, Iran were screened by VIA and Pap smear. The women with positive findings on one or both tests underwent colposcopy. Both sensitivity and specificity for VIA were found to be higher in this study. The sensitivity of VIA was found to be 74.3% compared with 72% for Pap smear. The specificity of VIA was 94% compared to 90.2% for Pap. Ghaemmaghami concluded that sensitivity and specificity of VIA is high comparable with that of cytology making it a feasible method of screening in countries where access to cytopathology is limited.

In 2003-2004, concurrent studies were performed by the **Alliance for Cervical Cancer Prevention (ACCP)**,⁸⁹ funded by the Bill and Melinda Gates

Foundation; across the world, looking at VIA as an alternative to PAP smears for cervical cancer screening. Studies reached India, Africa and Central America; where the majority of the cervical cancer burden lies. **Doh**⁹⁰ examined VIA as a screening method in Cameroon, Africa, where cancer of the breast and cervix contribute to over 45% of gynecological malignancies and is the most common cause of cancer deaths in women (Doh, International Journal of OB/Gyn 1994). All patients underwent VIA and PAP. If any of the two tests were positive, patients underwent colposcopy with biopsy and one out of ten "negative" cervixes were biopsied for control. Only acetowhite lesions with at least a border close to the squamo-columnar junction was considered as significant and positive. Lesions with faint borders were considered low grade and those with sharp borders were considered high grade. Negative cervixes had no white lesions. 4,813 women were screened. Sensitivity of VIA was 70.4 % vs. 47.7% for PAP. VIA specificity was 77.6% vs. 94.2% PAP. The positive predictive value of VIA was 44% and the negative predictive value of VIA 91.3%. Doh concluded that, although PAP has slightly better testing qualities, VIA has acceptable test qualities and may in low resource settings be implemented as a large-scale screening method.

In India, **Goel**⁹¹ examined 400 women between the ages of 30-34 attending the Gynae out patient clinic in New Delhi, India. The doctors performed Pap cytology, VIA and colposcopy on all 400 women. Goel found VIA to have a sensitivity of 96.7%, much higher than that of a Pap smear, which they found to be a mere 50%. The specificity of VIA, however, was much lower than the Pap smear, 36.4% vs. 97%. Goel found that VIA was a poor test for catching endocervical lesions, missing 2 cases in this study, and the low specificity of

VIA would result in high false positive rates. Overall, Goel concluded that VIA with acetic acid is very sensitive for ectocervical lesions; with its low cost and ease of use making it very advantageous for a primary screening method in developing countries. However, it does have a high rate of false positives, which if using the “see and treat method” would lead to over-treatment⁵⁰.

In rural areas of Northeast Brazil, **Bomfim**⁹² did a similar study. 1,154 women underwent Pap smear and VIA concurrently, with colposcopy if one or both screening tests were positive. Exams were conducted by either nurses or physicians. Sensitivity of VIA was found to be 100% vs 18% for Pap smears and specificity was 78% for VIA vs 100% for Pap smears in detecting low grade and high grade lesions. The positive predictive value (PPV) of VIA was 15.6% for LGSIL and 2.8% for HGSIL. The negative predictive value (NPV) of VIA was much better and found to be 100% for both. NPV of Pap smear was 97% and 99%. Bomfim concluded that VIA could be an excellent screening method for detecting cervical cancer and affirmed that both trained nurses and physicians would be capable of performing VIA assessment.

In urban Africa, Nairobi (Kenya), **De Vuyst**⁹³ studied VIA comparing it to three other screening methods, including HPV DNA typing. De Vuyst had 653 women undergo four concurrent screening methods: Pap smear, VIA, PCR for high risk HPV and cervicography. The gold standard for affirmative diagnosis was colposcopy and/or biopsy. Sensitivity and specificity were 83.3% and 94.6% for Pap smear, 73.3% and 80.0% for VIA, 94.4% and 73.9% for HR HPV PCR, and 72.3% and 93.2% for cervicography. Although Pap smear had the highest sensitivity and HPV PCR had the highest specificity, the visual inspections showed accuracy between the two. De Vuyst concluded that in poor resource countries VIA is effective as a primary screening tool⁵⁶.

A study was done by **Sankarnarayan et al.**⁹⁴ on accuracy of HPV DNA testing in primary screening of cervical neoplasia during the years of 1999-2003. The study involved 18,085 women aged 25-65 yrs in 3 different cities of India. The women also received testing with cytology. The reference standard for final diagnosis was a combination of colposcopy/ biopsy. The observed sensitivity and specificity of HPV DNA test was 45.7%-80.9% and 91%-95.6% respectively. The observed sensitivity and specificity of Pap smear cytology was 36.6%-72.3% and 87.2%-97.9% respectively.

In 2005, after many evidence-based articles substantiated VIA as an adequate screening method for cervical cancer, **Lawrence**⁹⁵ went to Guatemala and implemented a pilot study in evaluating VIA with the "see and treat" method. Lawrence looked at the acceptability of cervical screening using direct visual inspection after acetic acid application followed by immediate cryotherapy for CIN among women in rural Guatemala. Lawrence and colleagues offered cervical cancer screening to 1,052 Guatemalan women using VIA. 9.3% of patients deferred screening at all and refused examination. Among the 954 women screened, 13% were found to have findings consistent with CIN I or higher. 99% of the women with positive findings agreed to undergo immediate treatment with cryotherapy. This study showed that the "see-and-treat" method with VIA could be accepted by patients in developing countries. The drawback to this study was that it did not try to confirm the results of VIA by cytology or histology and treated assuming the VIA test was accurate. However, they noted that their rate of 13% abnormalities was comparable to the numbers found in other studies in the region.

Results of different studies have shown that VIA have yielded a range of

sensitivity and specificity values spanning from approximately 60 percent to over 90 percent.^{67, 73,96-100} While this range is narrower than observed for other tests including cytology (23% to 99% for sensitivity and 7% to 97% for specificity). For cervical cancer, the "gold" standard for establishing a diagnosis is biopsy.¹⁰¹ The VIA studies cited above have involved a variety of reference standard measures. These include: 100 percent biopsy sampling, a combined colposcopy/biopsy reference standard for all participants, biopsy for colposcopically-suspicious lesions only, and colposcopy with histology only for women test-positive on all screening tests i.e., VIA, Paps, HPV and cervicography.^{82,93,94,102} Subjective (human) error may have affected the quality of colposcopy or the quality of tissue collection, slide fixing and biopsy interpretation which could have led to misclassification of the reference standard.

References

1. World Health Organization. IARC screening Group- online documents- Cervical Cancer.[http:// screening.iarc.fr/doclib/cxca. Php lang = 1](http://screening.iarc.fr/doclib/cxca.php?lang=1). Accessed **2010**
2. Parkin DM. The global health burden of infection- associated cancer in the year 2002. *Int J Cancer*; 118: 3030- 3044, **2006**
3. Ferlay J, Shin HR, Bray F, Foran D, Mathers CD, Parkin DM. GLOBOCAN 2008: Cancer Incidence, Mortality and Prevalence Worldwide, Version 2.0. IARC Cancer Base No.10 Lyon, France: IARC. Available from: [http://globocan. Iarc.fr](http://globocan.iarc.fr), **2010**
4. Talukder H. Bangladesh National Institute of Cancer Research and Hospital, Directorate General of Health Services, Ministry of Health and Family Welfare. Annual Report, **2005**
5. Agustin A Garcia, MD. 'Cervical Cancer', Wikipedia, Updated: **2011**
6. Noller KL. Intraepithelial neoplasia of the lower genital tract (cervix, vulva): Etiology, screening, diagnostic techniques, management. In: Katz VL, Lentz GM, Lobo RA, Gershenson DM, eds. *Comprehensive Gynecology*. 5th ed. Philadelphia, Pa: Mosby Elsevier; chap 28, **2007**
7. Christine H. Holschneider, MD. Premalignant and Malignant Disorders of the Uterine Cervix. *Current obstetric and Gynecologic diagnosis and treatment*, 10th ed. McGraw-Hill, U.S.; 833-854; chap 50, **2007**
8. Datta DC. 'Cervical Intraepithelial Neoplasia' *Textbook of Gynaecology* 5th ed. New Central Book Agency (P) Ltd. Calcutta; 327-346, chap 21, **2009**

9. Cervical Cancer: Pathology, Symptoms and Signs, Diagnosis, Prognosis and treatment. American Health Network, Health. Am. Cervical Cancer statistics and prognosis, Cancer research, UK. Retrieved on **2007**
10. Janqueira, LC., Carneiro, J. The female reproductive system. In: Basic Histology and Atlas. The McGraw-Hill Companies: pp 451, **2003**
11. Shafi MI, Finn CB, Luesley DM. Lesion size and histology of atypical transformation zone. Br J Obstet Gynecol 98: 490-492, **1991** [Reviwed on **2010**]
12. Murthy NS, Mathew A. "Risk factors for pre-cancerous lesions of the cervix". European Journal of Cancer Prevention 9 (1): 5-14, **2000**
13. Burd EM. Human Papillomavirus and cervical cancer. Clinical Microbiology. Reviews 16:1-1721, **2003**.
14. Schiffman M, Kjaer SK. Natural history of anogenital human papillomavirus infection and neoplasia. J Natl Cancer Inst Monogr; (31):14-19, Chap 2, **2003**.
15. Kumar V, Abbas A K, Fausto N, and John A. Premalignant and malignant neoplasms of cervix. In: Robbins and Cotran, Pathological Basis of Disease. 8th ed., 1018-1024, Chap. 22, **2010**
16. Holowaty P, Miller AB, Rohon T. Natural history of dysplasia of the uterine cervix. J. Natl Cancer Inst 91: 252-258, **1999**
17. Ostor, A.G. Natural history of cervical intraepithelial neoplasia: a critical review. Int. J. Gynaecol Pathol. 12: 186-192, **1993**
18. Cervical cancer in adolescents: screening, evaluation, and management. Committee Opinion No. 463. American College of Obstetricians and

Gynecologists. *Obstet Gynecol* 116: 469–472, **2010**

19. Muñoz N, Bosch FX, de Sanjosé S, et al. "Epidemiologic classification of human papillomavirus types associated with cervical cancer.". *N. Engl. J. Med* 348 (6): 518–527, **2003**. Retrieved on **2007**.

20. Agorastos T, Miliaras D, Lambropoulos A, et al. "Detection and typing of human papillomavirus DNA in uterine cervixes with coexistent grade I and grade III intraepithelial neoplasia: biologic progression or independent lesions?" *Eur J Obstet Gynecol Reprod Biol* 121 (1): 99–103, **2005**

21. Thomas P, Stricker, Vinay K. Neoplasia. In: Robbins and Cotran *Pathological Basis of Disease*. 8th ed. 259-330, Chap. 7, **2010**

22. Cervical intraepithelial neoplasia: Overview, Risk Factors. From Wikipedia, the free encyclopedia; last modified on 3 May, **2012**

23. Munger K, Howley PM. Human Pappilomavirus immortalization and transformation functions. *Virus Res* 89: 213-228, **2002**

24. Walboomers JM, Jacobs MV, Manos MM, et al. "Human papillomavirus is a necessary cause of invasive cervical cancer worldwid e". *J. Pathol* 189 (1): 12–19. **1999**. Retrieved on **2007**

25. Giuliano AR, Siegel EM, Roe DJ, et al "Dietary intake and risk of persistent human papillomavirus (HPV) infection: the Ludwig-McGill HPV Natural History Study". *J. Infect. Dis*; 188 (10): 1508–1516, **2003**

26. Sushant F. Gray's anatomy. The pathogenesis of cervical neoplasia. In: *Diagnostic Cytopathology*. 39th edition. British Publication, London, England; 894-903, **2005**

27. Snijders PJ, Steenbergen RD, Heideman DA, Meijer CJ. "HPV-mediated cervical carcinogenesis: concepts and clinical implications." *J. Pathol* 208 (2):

152–164, **2006**

28. Murthy NS, Mathew A. "Risk factors for pre-cancerous lesions of the cervix". *European Journal of Cancer Prevention* 9 (1): 5–14, **2000**
29. Monnier-Benoit S, Dalstein V, Riethmuller D, Lalaoui N, Mougin C, Prétet J "Dynamics of HPV16 DNA load reflect the natural history of cervical HPV-associated lesions". *J Clin Virol* 35 (3): 270–277, **2006**
30. Committee on Practice Bulletins-Gynecology "ACOG practice bulletin. Diagnosis and treatment of cervical carcinomas, number 35, May 2002". *Obstetrics and gynecology* 99 (5 Pt 1): 855–867, **2002**
31. Ferenczy, A. and Franco, E. Persistent human papillomavirus infection and cervical neoplasia. *Lancet Oncol* 3: 11-16, **2002**
32. De Graaff J, Stolte LAM and Janssens J. Marriage and childbearing in relation to cervical cancer. *Europ J Obstet Gynec Reprod Biol* 7(5): 307-312, **1977**
33. Biswas LN, Manna B, Maiti PK and Sengupta S. Sexual risk factors for cervical cancer among Rural Indian women: A case-control study. *International Journal of Epidemiology* 26 (3): 492-495, **1997**
34. Castellsague X, Munoz N. Cofactors in Human papilloma virus carcinogenesis- role of parity, oral contraceptives and tobacco smoking. *Journal of the Cancer Institute Monograph* 31: 20-28, **2003**
35. Brinton LA, Reeves WC, Brenes MM, et al. Parity as a risk factor for cervical cancer. *Am J Epidemiol* 130(3): 486-496, **1989**

36. Winer RL, Hughes JP, Feng Q et al. Condom use and the risk of genital human papillomavirus infection in young women. *N Engl J Med* 354(25): 2645-2654, **2006**
37. Bosch FX, Burchell AN, Schiffman M et al. "Epidemiology and natural history of human papillomavirus infections and type-specific implications in cervical neoplasia". *Vaccine* 26 (Supplement 10): K1-16, **2008**
38. Ylitalo N, Sorensen P, Josefsson A, et al. Smoking and oral contraceptives as risk factors for cervical carcinoma in situ. *Int J Cancer* 81(3): 357-365, **1999**
39. Wright T.C. Jr, Subbarao S. et al. Human immunodeficiency virus 1 expression in the female genital tract in association with cervical inflammation and ulceration. *Am. J. Obstet. Gynecol*; 184: 279- 285, **2001**
40. John W. Sellors, R. Shankaranarayanan. *Colposcopy and Treatment of Cervical Intraepithelial Neoplasia: A beginner's Manual*. IARC, Lyon, France 13-20, Chap. 2, **2003**
41. *Cervical and Breast Cancer Screening Programme, Standards and Guidelines, Cervical cancer Screening and management*. Department of Obstetrics and Gynaecology, Bangabandhu Sheikh Mujib Medical University, Dhaka. 55-66, Chap. 6, **2007**
42. Koss LG. Melamed. *Koss's Diagnostic Cytology and its Histopathologic Bases*. 5th edition. A Wolters Kluwer Company pp. 293, **2006**
43. Grimes DA, Economy KE. Primary prevention of gynecologic cancers. *Am J Obstet Gynecol* 254-256, **1995**
44. JHPIEGO *Cervical Cancer Prevention: Guideline for Low-Resource Settings*- Baltimore, Maryland, **2005**

45. Planning and Implementing Cervical Cancer Prevention and Control Programs: A manual for managers. Seattle: Alliance for Cervical Cancer Prevention (ACCP), Washington, DC: Population Reference Bureau. **2004**
46. Cornelis JA., Hogewoning, Maaik CG. et al. "Condom use Promotes the Regression of Cervical Intraepithelial Neoplasia and Clearance of HPV: Randomized Clinical Trial". *International Journal of Cancer* 107 (5): 811–816, **2003**
47. Kent, A. "HPV Vaccination and Testing". *Reviews in obstetrics and gynecology* 3(1): 33–34, **2010**
48. Lowy DR, Schiller JT "Prophylactic human papillomavirus vaccines. " *J. Clin. Invest*; 116 (5): 1167–1173, **2006**
49. "Committee opinion no. 467: human papillomavirus vaccination". *Obstet Gynecol* **116** (3): 800–803, **2010**
50. "FDA Approves Expanded Uses for Gardasil to Include Preventing Certain Vulvar and Vaginal Cancers". Press release. Retrieved on **2009**
51. Harper DM, Gall S, Naud P, et al. "Sustained immunogenicity and high efficacy against HPV 16/18 related cervical neoplasia: Long-term follow up through 6.4 years in women vaccinated with Cervarix (GSK's HPV-16/18 AS04 candidate vaccine)." *Gynecol Oncol* 109: 158–159, **2008**
52. Kahn JA. HPV vaccination for the prevention of cervical intraepithelial neoplasia. *N Engl J Med*; 361:271-278, **2009**
53. Molly McAdams. ACOG Pap smears Guidelines, Mar 28. **2011**
54. World Health Organization Comprehensive cervical cancer control: A guide

to essential practice 15-191, **2006**

55. Wasti S., Ahmed W., Jafri A., et al. Analysis of cervical smear in a Muslim population. *Ann Saudi Med* 24(3): 189-192, **2004**

56. Mimi SA., Hena BSN., Khan MAH. and Bhuiyan MSH. Pap's smear: A study on Bangladeshi women in Sylhet. *OMTAJ* 1(1): 4-6, **2002**.

57. Ivanov S. The roll of the cytological screening, HPV- test and the colonoscopy for early detection of the precancerous lesions of the uterine cervix. *Akush Ginekol(Sofia)* 46(9): 45-49, **2007**

58. Gravitt P. New technologies in cervical cancer screening, *Vaccine* 26(Suppl.10): K42-K52, chap. 3, **2008**

59. R A Jahan, F Rahman, S M Badruddoza, et al. Role of VIA and Pap smear in the diagnosis of Cervical Precancer: A study of 115 cases. *TAJ* December; vol 22, No 2, **2009**

60. Di Bonito L, Falconeri G, Tomasic G et al. Cervical Cytopathology: an evaluation of its accuracy based on cytopathologic comparison. *Cancer* 72: 3002-3006, **1993**

61. Sherris J, Wittet S, Kleine A, et al. Evidence- based, alternative cervical cancer screening approaches in low- resource setting. *Int. Perspect Sex Report Health* 35(3): 147-154, **2009**

62. Hussain M, Nasir TA. Can VIA replace Pap smear as screening tool for cervical neoplasia: evaluation in 200 cases. *Bang J Pathol* 22(2): 2-9, **2007**

63. Gaffikin L, McGrath JA, Arbyn M, Blumenthal PD. BMC Visual inspection with acetic acid as a cervical cancer test: accuracy validated using latent class analysis. *Med Res Methodol*; 7:36, **2007**
64. Sankaranarayanan R. A critical assessment of screening methods for cervical neoplasia, *International Journal of Gynecology and Obstetrics* 89(Suppl.2): S4-S12, **2005**
65. Bhatla N, Mukhopadhyay A, Kriplani A, et al. Evaluation of adjunctive tests for cervical cancer screening in low resource settings. *Indian J Cancer* 44(2): 51-55, **2007**
66. Sankaranarayanan R, Basu P, Wesley RS, et al. Accuracy of visual screening for cervical neoplasia: results from an IARC multicentre study in India and Africa. *Int J Cancer* 110: 907-913, **2004**
67. University of Zimbabwe and JHPIEGO Cervical Cancer Project Visual Inspection with acetic acid for cervical-cancer screening: test qualities in a primary-care setting. *The Lancet* 353: 869-873, **2003**
68. Ahmed T, Ashrafunnessa, Rahman J. Development of a visual inspection program for cervical cancer prevention in Bangladesh. *Reproductive Health matters* 16(32): 78-85, **2008**
69. Singh Kavita N, More Shefali. Visual inspection of cervix with acetic acid (VIA) in early diagnosis cervical intraepithelial neoplasia (CIN) and early cancer cervix. *J Obstet Gynecol India* vol. 60, No.1, 55-60, **2010**
70. S. Nahar, R Sultana, Z Ferdous, A Khanam Evaluation of cervical cancer screening program in Khulna Medical College Hospital by simple visual inspection with acetic acid. *Bang Med J (Khulna)*; 42: 11-13, **2009**

71. Strander B. "At what age should cervical screening stop?" *Brit Med J* 338: 1022-1023, 2009
72. Sankaranarayanan R, Wesley R, Thara S, et al. Test characteristics of visual inspection with 4% acetic acid (VIA) and Lugol's iodine (VILI) in cervical cancer screening in Kerala, India. *Int J Cancer* 106: 404-408, 2003
73. Belinson J, Qiao YL, Pretorius R, et al. Shanxi Province Cervical Cancer Screening Study: a cross-sectional comparative trial of multiple techniques to detect cervical neoplasia. *Gynecol Oncol* 83: 439-444, 2001
74. Sankaranarayanan R, Esmey PO, Rajkumar R, et al. Effect of visual screening on cervical cancer incidence and mortality in Tamil Nadu, India: a cluster-randomized trial. *Lancet* 370: 398-406, 2007.
75. N. Li, J-F Shi, et al. Different cervical cancer screening approaches in a Chinese multicentre study. *British Journal of Cancer* 100: 532-537, 2009
76. Shastri SS. The role of low-level magnification in visual inspection with acetic acid for the early detection of cervical neoplasia. *Cancer Detect Prev*: 28(5): 245- 251, 200
77. Singer A., Monaghan JM. Lower Genital Tract Precancer Colposcopy, Pathology and Treatment. 2nd Edition, Blackwell Science, Oxford 70-120, 2000
78. Mitchell MF, Schottenfelt D, Tortolero-Luna G. et al. Colposcopy for the diagnosis of squamous intraepithelial lesions: Meta-analysis. *Obstet, Gynaecol* 91: 626-631, 1998
79. Anderson M., Joe J., Morse A., Sharp F. A text book and Atlas of International

80. De Vuyst H., Claeys P., Njiru S. et al. Comparison of Pap smear, visual inspection with acetic acid, human Papillomavirus DNA-PCR testing and cervicology. *Int J Gynaecol Obstet* 89(2):120-126, **2005**
81. Cronje HS, Parham GP, Cooreman BF, et al. A comparison of four screening methods for cervical] neoplasia in a in a developing country. *Am J of Obstet Gynecol* 188: 395-400, **2003**
82. Ivanov S. The roll of the cytological screening, HPV- test and the colonoscopy for early detection of the precancerous lesions of the uterine cervix. *Akush Ginekol (Sofia)*, **2007**
83. Agorastos T, Miliaras D, Lambropoulos A,et al. "Detection and typing of human papillomavirus DNA in uterine cervices with coexistent grade I and grade III intraepithelial neoplasia: biologic progression or independent lesions?" *Eur J Obstet Gynecol Reprod Biol* 121 (1): 99–103, **2005**
84. Ottaviano M, La Torre P. Examination of the cervix with the naked eye using acetic acid test. *Am J Obstet Gynaecol* 143: 39-42, **1982**
85. Sehgal A. Screening of uterine cervical cancer using VI-aided and unaided, and colposcopic screening. Presented at the National conference on early detection of cervical cancer-Alternative strategies; Jan 6-8, Delhi, India, **2001**
86. Gaffikin L., Lauterbach M. and Blumenthal P.D. Performance of visual inspection of acetic acid for cervical screening: a qualitative summary of evidence to date. *Obstet Gynaecol Surv* 58(8): 543-550, **2003**

87. Ngelangel CA, Limson GM, Cordero CP, et al. Acetic acid guided visual inspection vs. cytology-based screening for cervical cancer in the Philippines. *Int J Gynaecol Obstet* 83: 141-150, **2003**
88. Ghaemmaghani F. Visual inspection with acetic acid as a feasible screening test for cervical neoplasia in Iran. *Int J Gynecol Cancer* 14(3): 465-469, **2004**
89. Planning an Implementing Cervical Cancer Prevention and Control Programs: A manual for managers. Seattle: Alliance for Cervical Cancer Prevention (ACCP), **2004**
90. Doh AS, Nkele NN, Achu P, Essimbi F, Essame O, Nkegoum B. "Visual Inspection with acetic acid and cytology as screening methods for cervical lesions in Cameroon." *Int J Gynaecol Obstet* 89(2):167-73, **2005**
91. Goel A, Gandhi G, Batra S, et al. Visual inspection of the cervix with acetic acid for cervical intraepithelial lesions. *International Journal of Gynecology and Obstetrics* 8: 25-30, **2005**
92. Bomfim, S. "Visual Inspection with acetic acid for cervical cancer detection". *International Journal of Gyn and OB* 88, **2005**
93. De Vuyst, H "Comparison of Pap smear, visual inspection with acetic acid, HPV DNA-PCR testing and cervicography." *International Journal of Gyn and OB* 89, **2005**
94. Sankaranarayanan R, Chatterji R, Shastri SS, et al. Accuracy of human papillomavirus testing in primary screening of cervical neoplasia: results from Multicentre study in India. *Int J Cancer*. 116(5): 830-831, **2005**

95. Lawrence, MJ, Wigton, TR, Leonhardt, JG. "Screening for Cervical Neoplasia in an unselected rural Guatemalan Population Using Direct Visual Inspection after Acetic acid application: A pilot study." *Journal of Lower Genital Tract Disease*; 9(4): 232-235, **2005**
96. Shankaranarayanan R, et al. Effectiveness, safety and acceptability of 'see and treat' with cryotherapy by nurses in a cervical screening study in India, *British Journal of Cancer*; 96 (5):738-743, **2007**
97. Denny L. Screen-and-treat approaches for cervical cancer prevention in low resource settings: a randomized controlled trial, *Journal of the American Medical Association* 294(17): 2173-2181, **2005**
98. Luciani S. Effectiveness of cryotherapy for cervical intraepithelial neoplasia, *International Journal of Gynecology and Obstetrics*; 101(2): 172-175, **2008**
99. Rodriguez-Reyes ER, Cerda-Flores RM, Quinonez-Perez JM, Velasco-Rodriguez V, Cortes-Gutierrez EI. Acetic acid test: a promising screening test for early detection of cervical cancer. *Anal Quant Cytol Histol.* 24:134-6, **2002**
100. Sankaranarayanan R, Rajkumar R, Theresa R, et al. Initial results from a randomized trial of cervical visual screening in rural south India. *Int J Cancer* 109: 461-7, **2004**.
101. Paskorn Sritipsukho, Yuthadej Thaweekul. Accuracy of Visual Inspection with Acetic Acid (VIA) for Cervical Cancer Screening: A Systematic Review S254 *J Med Assoc Thai* Vol. 93 Suppl. **2010**
102. Wasti S, Ahmed W, Jafri A, et al. Analysis of cervical smear in a Muslim population. *Ann Saudi Med* 24(3): 189-92, **2004**

Chapter-II

Statement of the work

2.1 General objective:

- To evaluate VIA as a screening method in detecting precancerous and early cancerous lesion of the cervix.

2.2 Specific objectives:

- To find out the socio demographic characteristic of the patients.
- To find out the risk factors for cervical cancer.
- To assess the role of VIA in detection of cervical lesion.
- To assess the role of colposcopy in the detection of cervical lesions.
- To confirm final diagnosis by histopathology.
- To estimate the sensitivity, specificity and predictive values of VIA as a primary screening method for cervical intraepithelial neoplasia.(CIN).
- To estimate the sensitivity, specificity and predictive values of colposcopy
- To find out the association of HPV-DNA in precancerous and cancerous lesions of the cervix.
- To reduce the morbidity and mortality related to cancer of the cervix.

Chapter-III

Experimental

3. Materials and Methods

3.1 Introduction:

This experimental work in connection with the detection of precancerous and cancerous lesions of the cervix with visual inspection after acetic acid, colposcopy and histopathology, Pap smear and HPV-DNA test are being presented in the subsequent chapters. The details of some experimental procedures are presented here to minimize any unnecessary repetition.

3.2 Study design and participants: This cross-sectional study was carried out in Rajshahi Medical College Hospital (RMCH) during the period of July 2007 to December 2010. Women attending Gynae OPD or Maternal and Child Health clinics for any Gynaecological problem were referred to VIA Centre.

3.3 Inclusion Criteria:

1. Married women at or above 30 years of age.
2. Earlier in patients at risk (marital life more than 10 years.)
3. Women with suspected or known sexually transmitted infection (STI)
4. Clinically symptoms and signs suggestive of early cervical cancer (history of vaginal discharge, irregular per vaginal bleeding, post coital bleeding, lower abdominal pain etc.)
5. Patients with clinically unhealthy looking cervix.

3.4 Exclusion Criteria:

1. Women having no sexual contact.

2. Any Visible lesion on cervix in naked eye.
3. Carcinoma cervix.
4. Menstruating women with heavy flow.

3.5 Methods of data collection: The patients were interviewed by a female nurse who used a questionnaire. The study objectives were explained and verbal consent was obtained. Basic demographic informations including age, educational attainment, occupation, religion, family income was collected. Prior cervical screening history and presence of gynecological complains, a detailed reproductive and contraceptive history was also assessed. Clinical history, physical findings, VIA, colposcopy and histological findings were recorded in the pre-designed patient's profile made for the study.

3.6 Outcome measures

The reference standard used in our study was colposcopy with biopsy (whenever the latter was clinically indicated)—a commonly accepted reference standard for cervical cancer screening studies. We defined two thresholds of disease: a low threshold of low-grade squamous intraepithelial lesion (LSIL) or worse on colposcopy (or their equivalents on biopsy); and a high- grade squamous intraepithelial lesion (HSIL) or worse. LSIL or more was taken as a positive test for Pap smear. We define a positive test for VIA as either CIN or cancer, as shown by acetowhite lesions and other visual markers of precancerous lasions of the cervix.

Ethical clearance of this research work was approved by Ethical Review Committee of Research cell of Rajshahi Medical College, Bangladesh (ref. RMC/ER/2010-2013/01)

3.7 Equipments and materials for VIA

- Examination table with knee crutches or leg rests
- Good light source
- Instrument tray or container
- Galipot
- Sterile bivalve speculum (CUSCO's or Grave's)
- Pair of gloves
- Cotton swabs, cotton-tipped buds, gauze
- Sponge holding forceps
- Dilute acetic acid (3-5%) solution
- Record form to record the findings
- Container with 0.5% chlorine solution to decontaminate the instruments



Fig 3.1: Equipments and materials for VIA

Procedure of VIA

After proper counseling, the patient was placed in lithotomy position. Cervix was exposed by cuscus vaginal speculum. Any evidence of vaginal discharge or any other lesions on the external genitalia and perineal region were observed. *The light source was adjusted so that there was adequate light in the vagina and on the cervix.* If there was excess mucous or discharge, it was cleaned with a cotton swab soaked in normal saline solution. The external os, columnar epithelium (red in color), squamous epithelium (pink) and the squamo columnar junction (SCJ) and transformation zone (TZ) were identified. Any abnormal finding was observed. Then 5% acetic acid using a cotton swab was applied on the cervix. After at least 1 minute, the cervix including the entire SCJ and TZ were inspected for any acetowhite change and carefully observed to note:

- Location of the lesion.
- Size (extent or dimensions) and number of the lesions.
- The intensity of the white color of the acetowhite lesion.
- The borders and demarcations of the white lesion:
 - Distinctly clear and sharp or indistinct diffuse margins,
 - Raised or flat margins,
 - Regular or irregular margins.
- Whether the lesions are uniformly white in color or the color intensity varies across the lesion or if there are areas of erosion within the lesion.
- How rapidly the acetowhite lesion appeared and then disappeared was also noted.
- To see whether the cervix bleeds easily.

Detection of distinct, well-defined, dense, acetowhite area with regular or irregular margins close to squamocolumnar junction (SCJ) or in transitional

zone (TZ) or dense, aceto-white ulceroproliferative growth on the cervix constitute positive VIA. In absence of these changes the test was interpreted as VIA Negative.

Colposcopy was performed in all women with positive VIA. Scoring was done using Reid combined colposcopic index and a Reid score greater than 2 was considered positive. Biopsies were taken from the suspected area and sent for histopathology.

The results of the test (either positive or negative) were discussed with the women and appropriate treatment offered after proper counseling.

VIA negative patients asked for repeat VIA after 3 years.

Women with suspected invasive cancers referred for further investigations and treatment.

3.8 Colposcopy

Instruments and materials require for colposcopy:

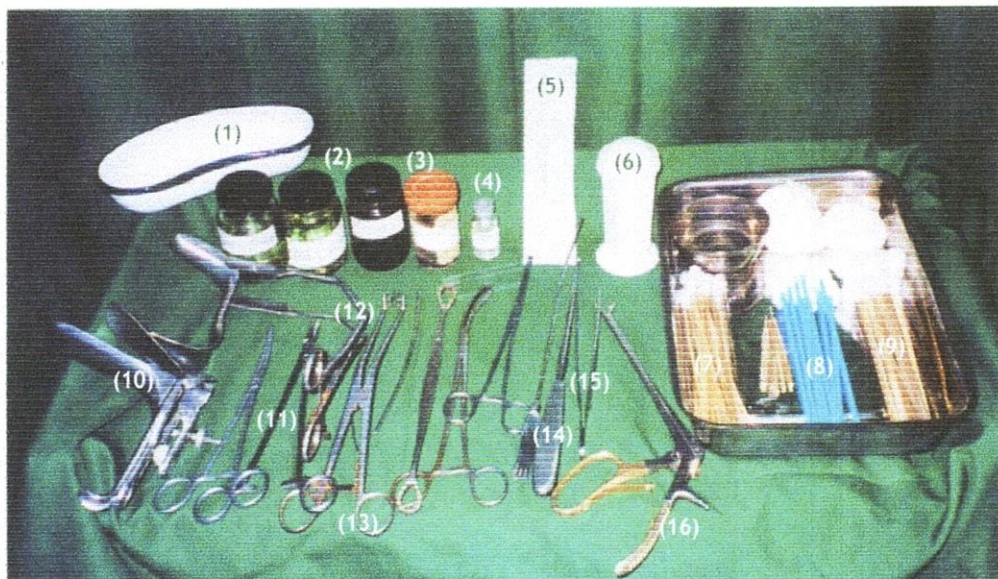

Fig 3.2: Instruments and materials require for of the colposcope

- | | |
|--|---------------------------------------|
| 1. Kidney tray | 8. Cervical cytology brushes |
| 2. Bottles with normal saline,
5% acetic acid and Lugol's
iodine | 9. Large Cotton-tipped swab
sticks |
| 3. Monsel's solution | 10. Vaginal speculum |
| 4. Bottle containing formaline | 11. Sponge holding forceps |
| 5. Local anaesthetic syringe | 12. Vaginal side-wall retractor |
| 6. Jar containing alcohol for
cervical smear fixation | 13. Endocervical speculum |
| 7. Cotton-tipped fine swab
sticks | 14. Endocervical curette |
| | 15. Dissecting forceps |
| | 16. Punch biopsy forceps |

In our center we use Video Colposcope, GOLDWAY SLC-2000 series having high speed auto/manual focusing: 1-25x optical magnification camera (SLC-2000 A/ 25x SLC-2000 B) and working distance 200-300 mm. Lower magnification yields a wider view and greater depth of field whereas, higher magnification may reveal finer feature such as abnormal blood vessels.

Procedure of Colposcopic examination:

Colposcopic findings are evaluated in conjunction with the history, clinical examination findings and on the cervical screening report. The patient was placed in lithotomy position. The height of the table was adjusted. Colposcope was kept on left side of a right-handed person or vice versa. All the instrument and reagents were available on a trolley nearby on the right side. No lubricant was used during vaginal examination prior to colposcopy. Bivalve self retaining vaginal speculum inserted into the vagina. As soon as the cervix was visible both the blades were opened sufficiently and fixed. Care was taken not to

traumatize the cervix as it may initiate bleeding hampering the Colposcopic examination. With one hand the speculum was manipulated while with the other hand colposcope was brought forward and focused on the cervix.

Steps of Colposcopic examination:

Inspection of unstained cervix: After exposing the cervix, the nature of the cervico-vaginal secretions and any obvious findings such as ectropion, polyp, nabothian follicles, congenital transformation zone, atropy, inflammation and infection, leukoplakia (hyperkeratosis), condylomata, ulcer, growth and any obvious lesions in the vaginal fornices were noted. Following this, excess mucous were removed gently from the cervix with saline-soaked cotton swabs.

Examination through the green filter: The next necessary step in colposcopy was to visualize the vascular pattern of the cervix by inserting green filter. Blood vessels stand out as black streaks against background of translucent epithelium. Number of vessels, their caliber, tortousity, patterns and intercapillary distance were noted.

Inspection after application of Acetic acid: Acetic acid causes the sharpest contrast between normal and abnormal epithelium. Wiping the cervix a few times with the swab assists in the coagulation and removal of mucous which in turn help the acetic acid to penetrate to the epithelium in full strength. The acetowhitening effect of acetic acid develops gradually over the course of 60 seconds and the effect may fade afterwards. Hence, acetic acid reapplied every 2-3 minutes during the examination.

Application of lugol's iodine (Schiller's test): Application of iodine clearly delineates the borders of a lesion before a biopsy, or treatment of the lesion is attempted.

To perform cervical biopsy, if necessary: Once an abnormal transformation zone was detected, the area was evaluated and compared with other areas of the cervix. Then punch biopsy or biopsies were taken from the suspected area. The tissues were fixed, labeled properly and sent for histopathological examination. The biopsy sites cauterized with Monsel's paste or with a silver nitrate stick immediately after the procedure to control any bleeding. Serial documentation of colposcopic findings is very important for follow up to analyze progression or regression of the disease process. Colposcopy is purely visual method, findings cannot be measured. So colposcopic findings were documented by photography and by hand drawings. Position of squamo columnar junction and extent of transformation zone was noted. Biopsy sites were also noted.

3.9 The technique followed for the Histopathological Examination

Collection of specimens

Specimens were obtained by colposcopic guided punch biopsy from the visible aceto-white lesions. In addition, biopsy specimens were taken from any lesions that were suggestive of cancer.

Gross Examination

The specimens were examined in the department of Pathology, Rajshahi Medical College, Rajshahi with a particular emphasis on number, diameter, size, shape, colour, and consistency.

Tissue processing and staining of histopathology slides

Routine tissue processing with paraffin impregnation was done. For microscopic examination routine paraffin sections were stained with hematoxylin and eosin staining method.

Preparation of Haematoxylin and Eosin stains (H and E)

Harri's haematoxylin: Ingredients

Haematoxylin crystal	5.0 gm
95% alcohol	50 ml
Ammonium or potassium alum	100 gm
Distilled water	950 ml
Mercuric acetic acid (red)	2.5 ml
Glacial acetic acid	40 ml

Procedure: Haematoxylin crystals were dissolved in 95% alcohol, at 56⁰C in an oven. Ammonium or potassium alum was dissolved in distilled water by heating. Two solutions were then mixed and brought to boil rapidly and continued for one minute with frequent stirring, then it was removed from the flame and mercuric oxide was added slowly. It was then reheated until the solution become dark purple. The mixture was then allowed to cool rapidly in cold water. The stain was ready for use after cooling and kept at room temperature. 2 to 4 ml of glacial acetic acid was added per 100 ml of solution of enhance precision of nuclear stain. It is filtered before use.

b. Acid alcohol: Ingredients:

Hydrochloric acid (pure	01 ml
70% ethyl alcohol	99 ml

Procedure: 1 ml. of hydrochloric acid is added to 99 ml of 70% ethyl alcohol and mixed thoroughly.

c. Eosin solution (stock): Ingredients:

Eosin (water soluble) Powder	01 ml
Distilled water	100 ml

d. Eosin solution (working):

Stock eosin solution	25 ml
70% alcohol	75 ml

Procedure: Eosin was dissolved in distilled water and mixed thoroughly. It was stored at room temperature and filtered before use.

Preparation of Papanicolaou's stain:

Harri's Haematoxylin (only for papanicolau's stain):

Haematoxylin (dark crystals)	8 gm
95% ethyl alcohol	80 ml
Aluminium ammonium sulphate	160 ml
Distilled water	1600 ml
Mercuric oxide	6 gm

Procedure: Aluminium ammonium sulphate was dissolved in water by heating. Haematoxylin crystals were dissolved in 95% ethyl alcohol and mixed with sulphate solution. The mixture was boiled to 95⁰C. The flame was then removed and the mercuric oxide was added slowly by stirring the mixture. The mixture was then allowed to cool into a cold water bath. The mixture was then filtered. This is the stock Harri's haematoxylin solution. For use, the required amount of solution was diluted with an equal amount of distilled water and filtered again.

3.10 Data Collection

All the necessary information and clinical data collected for each of the study patients were systematically recorded in a pre designed questionnaire sheet.
(Appendix III)

3.11 Statistical Analysis

All data were compiled and analyzed manually by preparing a master sheet. Statistical interpretations were done by using SPSS (Statistical Package for the Social Science). Various indices such as false positive, false negative, sensitivity, specificity, accuracy, predictive value of positive and predictive value of negative were calculated. P value, < .05 was taken as minimum level of significance.

Statistical methods:

1. Sensitivity
2. Specificity
3. Positive Predictive value (PPV)
4. Negative Predictive value (NPV)
5. Efficiency
6. Accuracy

The validity of cytology refers to its ability to diagnose cases of cancer and distinguish them from non-malignant conditions. Validity would have 100% sensitivity and specificity.

1. Sensitivity: Sensitivity measures how well a test identifies truly ill people. It represents the proportion of subjects with a disease, which a test is diagnosed correctly as such by a definite test.

$$\text{Sensitivity} = \frac{\text{Test positive}}{\text{Disease positive}} \times 100\%$$

Sensitivity is calculated by dividing the number of true positives by the sum to the number of true positives and false negative multiplied by 100 to yield a percentage.

True positive: They are ill people whom a test has correctly identified as being ill i.e. those who have positive test results and the disease.

False negative: They are ill people whom a test has incorrectly identified as being well i.e. those with negative results who have the disease.

Specificity: it measures how well a test identified truly well people. It is the proportion of subjects without a condition, which a test will designate a negative. In other words, it is the percentage of well people diagnosed correctly by a definite test.

$$\text{Specificity} = \frac{\text{Test negative}}{\text{Disease negative}} \times 100\%$$

1. **True Negative:** They are well people whom a test has correctly identified as being well.

2. **False positive:** They are well people whom a test has incorrectly identified as being ill.

3. **Positive Predictive value (PPV):** Is the probability that a person with positive test is a true positive i.e. does have the disease.

$$\text{PPV} = \frac{\text{True positive}}{\text{True positive} + \text{False positive}} \times 100\%$$

4. **Negative Predictive value (NPV):** Is the probability that a person with negative test is true negative i.e. does not have the disease.

$$\text{NPV} = \frac{\text{True negative}}{\text{True negative} + \text{False negative}} \times 100\%$$

5. **Efficiency:** if the test defines a test correctly identified the ill people.

$$\text{Efficiency} = \frac{\text{True positive} + \text{True negative}}{\text{True positive} + \text{False positive} + \text{False negative} + \text{True negative}} \times 100\%$$

6. Accuracy: It is the percentage of total number of positive cases identified correctly, i.e. percentage of benign and malignant lesion identified correctly.

$$\text{Accuracy} = \frac{\text{True positive} + \text{True negative}}{\text{True positive} + \text{False negative} + \text{False positive} + \text{True negative}} \times 100\%$$

Chapter IV

Study no I

**Early Detection of Cervical Intraepithelial Lesions
by Simple Visual Inspection after Acetic Acid
among Women in Rajshahi Medical College
Hospital**

4.1 Introduction:

There is compelling evidence that organized cytology screening programs have substantially reduced the incidence of and mortality from cervical cancer in developed countries.¹⁻³ Such models of screening, based on call, recall and repeat cytology at regular intervals over a long period of time, are difficult to organize in most developing countries due to a variety of fiscal and technical constraints.^{4,5} Additionally, only a small percentage of women with positive Pap smears have diagnostic evaluation and treatment, because of the lack of health centers that are able to treat preinvasive lesions.^{6,7} On the other hand, cervical cancer continues to be a major public health problem in these countries, and cervical cancer control measures are a major priority in reducing premature death and disability during the most productive period in a woman's life.⁸

The problems with Pap smears have stimulated research on alternative tests. Among them, one method, direct visualization with acetic acid (VIA) has gained popularity and proven itself in many clinical trials as an adequate alternative to Pap smears in developing countries.⁹⁻¹²

VIA has a potential advantage over traditional screening techniques in poorly resourced locations- there is immediate feedback of test results to the patient and importantly, treatment can be provided immediately after the test.¹³⁻¹⁶ If the test is negative, the patient can be told immediately without having to return to the doctor for results. In rural areas where people travel hours for a doctors' visit, a screening method requiring fewer visits will have a much higher success rate.¹⁷⁻¹⁹ Therefore, the main objective of this study phase was to assess whether the aided visual inspection using acetic acid could be use as an alternative modality to detect early cervical cancerous and precancerous lesions among women in RMCH.

4.2 Materials and Methods

This was a cross-sectional, screening test study that took place from July 2007 to December 2008 in Rajshahi Medical College Hospital, Gynae Out Patient Department (OPD).

Inclusion criteria, exclusion criteria and all other necessary information like basic demographic information including age, educational attainment, occupation, religion and family income were collected. Prior cervical screening history and presence of gynecological complains, a detailed reproductive and contraceptive history was also assessed. Clinical history, physical findings, VIA, colposcopy and histological findings for each of the study patients systematically recorded in a pre designed questionnaire sheet (described in details in chapter III and in Appendix III).

4.2.1 Procedure of VIA described in chapter III.

4.2.2 Procedure of colposcopy described in chapter III.

4.2.3 Procedure of histology described in chapter III.

In this study phase, 5593 women were screened using VIA. Among the VIA positive cases, distinct acetowhite areas were further categorized as VIA positive grades 1, 2 and 3 according to the severity. Those who had abnormal results in screening test and those who had clinically suspicious lesions were sent for colposcopic evaluation and directed biopsies were taken from colposcopically suspected areas. The final diagnosis was based on histology.

All patients who tested positive on colposcopy underwent LEEP (Loop Electrosurgical Excision Procedure) under local anaesthesia or cryotherapy as an outdoor procedure. The tissue obtained was sent for histopathologic evaluation.

The lesions found mildly dysplastic or worse on histopathologic evaluation were considered true positive cases.

VIA negative patients had asked for to repeat VIA after 3 years.

Women with suspected invasive cancers referred for further investigations and treatment.

4.3 Statistical Analysis

All data had compiled and analyzed manually by preparing master sheet. Statistical interpretations had done by using Statistical Package for the Social Science (SPSS) program software. (described in details in chapter III)

4.4 Study Results:

Study cases had been chosen from non virgin women who came to Gynae Out patient Department of Rajshahi Medical College Hospital from July 2007 to December 2008.

Out of 5593 patients studied, the patients had an age spectrum between 21 to 60 years with mean age 36.1 (SD \pm 1.5) years (Figure 4.5.1)

Among the study patients, 671(12%) had no symptoms, only they came for screening purpose. Intermenstrual bleeding, post coital bleeding, heavy irregular vaginal bleeding were found in 1958 (35%), 783 (14%), 336 (06%) women respectively. Dirty brown white discharge was the complaints in more than half of the cases 3020 (54%), lower abdominal pain was the second highest complaints 2460 (44%) shown in Figure 4.5.2

On speculum examination, apparently healthy cervix was observed in 2908 (52%) cases. Cervical lesions such as erosion or ectropion, polyp, cauliflower like growth and nodular/ nabothian cysts were observed in women are shown in Figure 4.5.3

To find out the probable causes of cervical cancer, we have collected epidemiological data regarding age of first coitus and first delivery, history of extramarital exposure and sexually transmitted infection, use of contraceptive methods, family history of cancer and socioeconomic status from 442 VIA positive cases 203 (46%) women had first coitus between 12 to 15 years and second highest were 177 (40%) between 16 to 20 years. More than half of the patients, 274 (62%) delivered their first baby between 15-20 years, age below 15 years was 53 (12%), 88 (20%) between 21-25 years and 27 (06%) delivered first above 25 years. Regarding history of exposure, 75 (17%) had extramarital exposure. Previous history of sexually transmitted infection was present only 09 (2%) methods used were cases. The oral contraceptive pills (OCP), Injectable

contraceptives and barrier 339 (54%), 75 (17%), 44 (10%) respectively. 84 (19%) patients did not use any contraceptive. Regarding socioeconomic status, most of the patients 256 (58%) belonged to lower middle group and second highest, 111 (25%) was middle group (Table 4.5.1).

In this study, among 5593 patients, 442 (7.90%) were found to have positive findings on VIA (Figure 4.4.5). VIA positive patients were examined by colposcopy which showed normal appearance with no evidence of dysplastic lesions in 228 (51.58%) patients. Remaining 214 cases with abnormal colposcope were subjected to directed biopsy (Figure 4.5.6). On histology, 29 (13.55%) found to have CIN-1, CIN-II 06 (2.81%) and CIN III/carcinoma in situ 06 (2.81%) The seventeen cases (7.94%) of invasive carcinoma were confirmed by biopsy (Table 4.5.2).

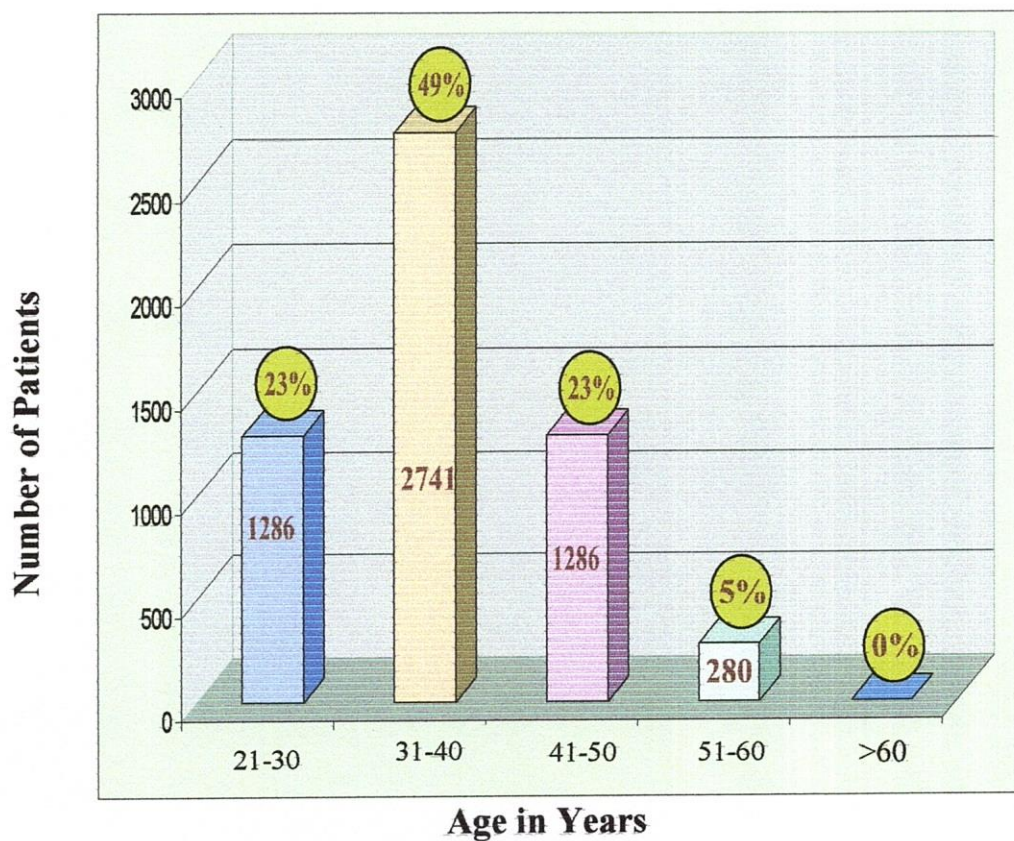


Figure 4.4.1: Age distribution of the screened patients (n = 5593).

Bar diagram shows, the age range of the study patients was 21 to 60 years. The patients were divided into four groups considering each decade as a single group. Out of 5935 patients 1286(23%) belonged to the age group 21-30 years, 2741 (49%) were 31-40 years, 1286 (23%) were 41-50 years, 280 (5%) were 51-60 years age group.

n indicates number of patients

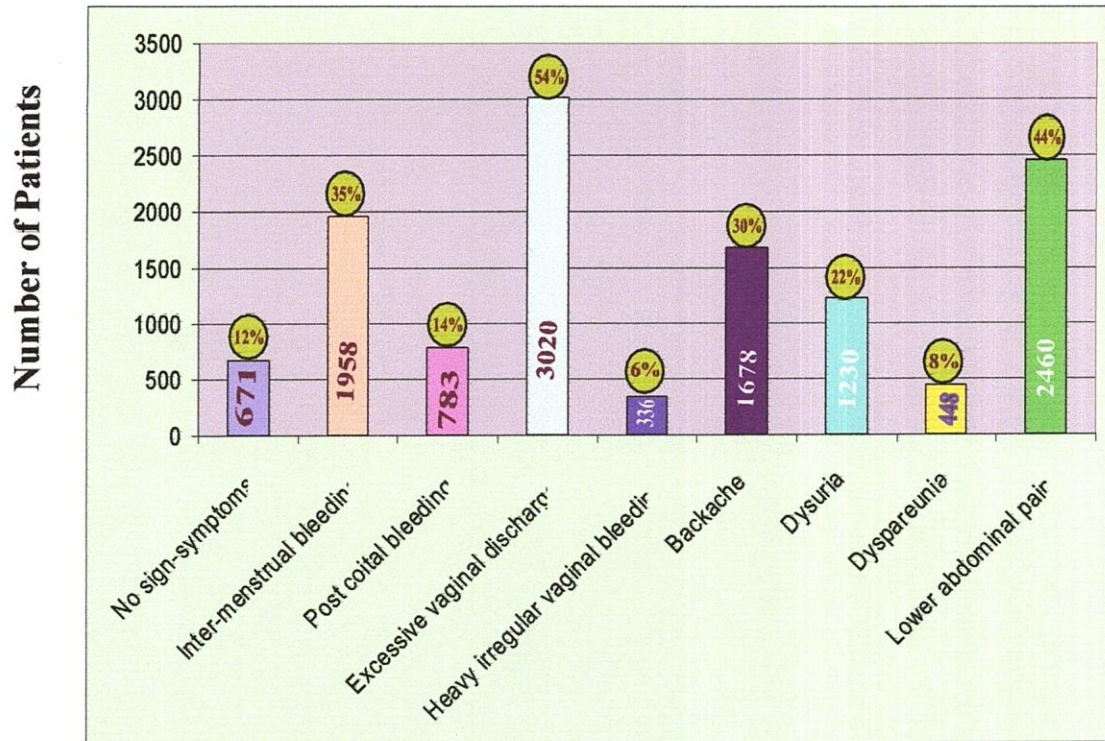


Figure 4.4.2: Distribution of symptoms of the screened patients (n= 5593).

Bar diagram-shows, among the study patients, 671(12%) had no symptoms, Intermenstrual bleeding, post coital bleeding, heavy irregular vaginal bleeding were found in 1958(35%), 783(14%), 336(06%) women respectively. Dirty brown white discharge was the complaints in more than half of the cases 3020(54%), lower abdominal pain was the second highest complaints 2460(44%), and other symptoms are shown in Fig 4.5.2

n indicates number of patients

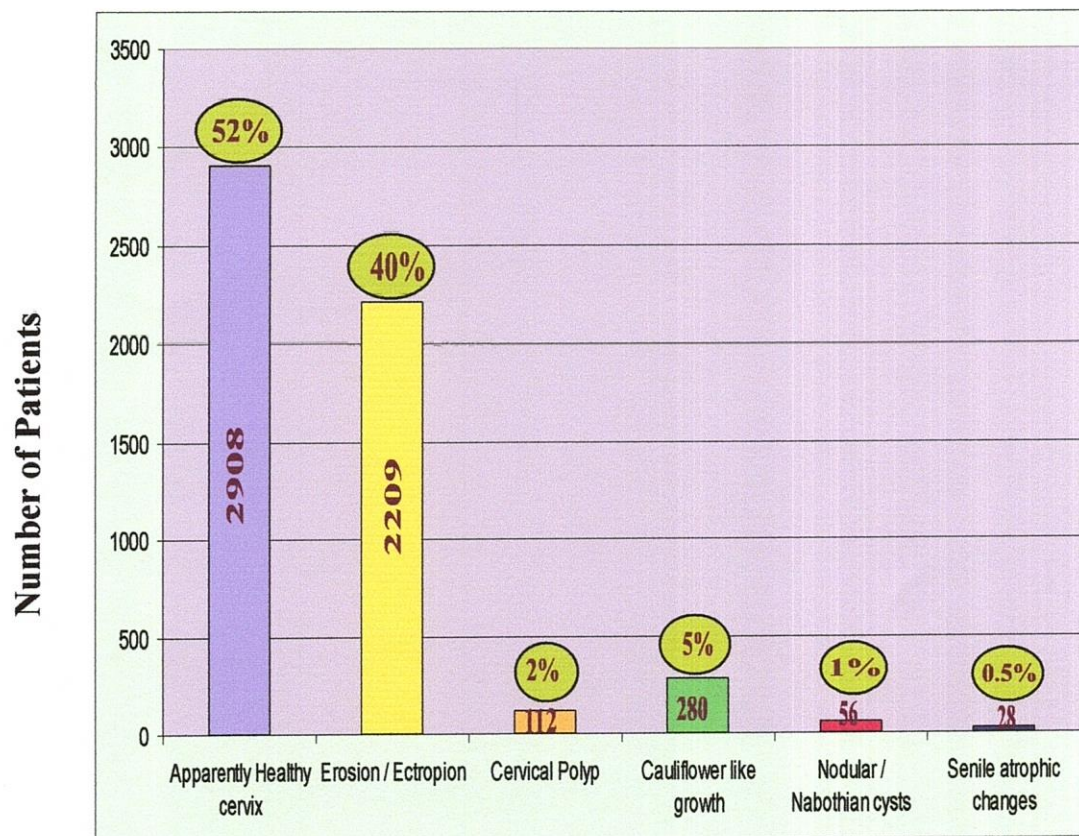


Figure 4.4.3: Distribution of speculum examination findings of the screened patients (n=5593).

Bar diagram-shows, apparently healthy cervix in 2908 (52%) cases. Cervical lesions such as erosion or ectropion, polyp, cauliflower like growth and nodular/ nabothian cysts were observed in 40%, 2%, 5%, 1% and 0.5% cases respectively.

n indicates number of patients

Table 4.4.1: Findings regarding the risk factors of cervical cancer in VIA positive cases (n= 442)

Variables	Number	Percent
Age of first coitus		
< 12 years	22	05%
12-15 years	203	46%
16-20 years	177	40%
21-24 years	27	6%
25 or above years	13	3%
Age of first delivery		
< 15 years	53	12%
15-20 years	274	62%
21-25 years	88	20%
> 25 years	27	06%
History of extramarital exposure		
No	367	83%
Yes	75	17%
History of STI		
Yes	09	02%
No	433	98%
Use of Contraceptive Methods		
Oral contraceptive pill	239	54%
Injectable	75	17%
Barrier	44	10%
No	84	19%
Family history of cancer		
Yes	40	09%
No	402	91%
Socio Economics Status		
Lower (income <3000/- per month)	35	8%
Lower middle(income 3000/- 6000/- per month)	256	58%
Middle(income > 6000/- 10,000/- per month)	111	25%
Upper >10,000 per month	40	9%

Table 4.4.1 shows, among 442 VIA positive cases, 203(46%) women had first coitus between 12 to 15 years and second highest were 177(40%) between 16 to 20 years. More than half of the patients, 274(62%) delivered their first baby between 15-20 years, age below 15 years was 53(12%), 88(20%) between 21-25 years and 27(06%) delivered first above 25 years. Regarding history of exposure, 75(17%) had extramarital exposure. Previous history of STI was present only 09(2%) cases. The OCP, Injectable contraceptive and barrier methods used were 339(54%), 75(17%), 44(10%) respectively. 84(19%) patients did not use any contraceptive. Regarding socioeconomic status, most of the patients 256(58%) belonged to lower middle group and second highest, 111(25%) was middle group.

n indicates number of patients

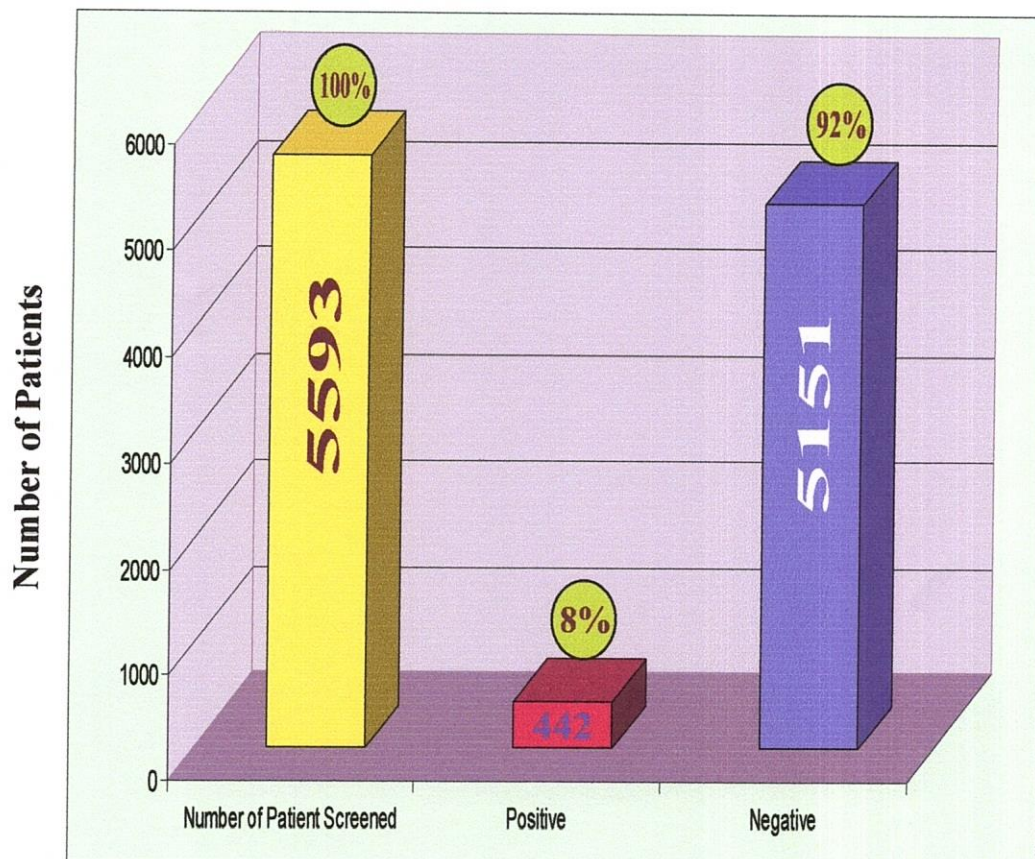


Figure 4.4.4: Screening result of VIA (n= 5593).

Bar diagram-shows among 5593 patients, 442(7.90%) were on VIA positive and 5151(92.10%) were VIA negative.

n indicates number of patients

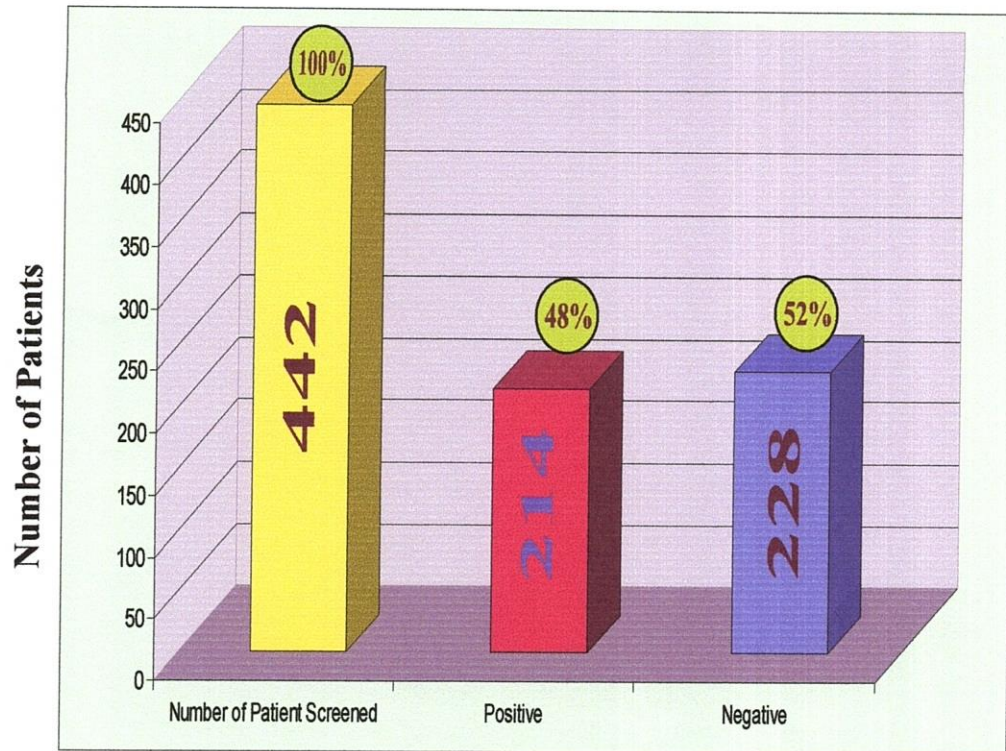


Figure 4.4.5: screening result of Colposcopy (n= 442).

Bar diagram-shows normal appearance with no evidence of dysplastic lesions in 228(51.58%) patients. Remaining 214 (48%) cases with abnormal colposcope were subjected to directed biopsy.

n indicates number of patients

Table 4.4.2: Percentage detection of different lesions by VIA, Colposcopy and Histopathology.

	VIA (n=5593)	Colposcopy (n=442)	Histopathology (n=214)
Negative/Normal/ Chronic cervicitis	5151 (92.10%)	228 (51.59%)	156 (72.90%)
Positive	442 (7.90%)	214(48.40%)	58(27.10)
CIN-I	405 (91.23)	149 (33.72%)	29 (13.55%)
CIN-II	20 (4.52%)	27 (6.1%)	06 (2.81%)
CIN-III/ Carcinoma-in-situ	07 (2.04%)	09 (2.03%)	06 (2.81%)
Invasive carcinoma	10 (2.21%)	12 (2.71%)	17 (7.94%)

Table 4.4.2 shows, out of 5593 patients screened, 5151 (92.8%) were VIA negative and 442 (7.2%) were VIA positive. VIA positive patients were colposcopically evaluated (n=442). Among them, 228 were colposcopically normal and 214 had different stages CIN and carcinoma cervix. Out of 214 colposcopically positive patients biopsied, 156 had chronic cervicitis (chronic inflammatory changes in cervix), 41 patients had a final diagnosis of CIN lesions and seventeen cases of invasive carcinoma. From the above findings, it is observed that out of 442 VIA positive cases, 214 cases were colposcopically positive and out of 214 colposcopically positive cases only 58 cases had histologically proven CIN lesion and invasive cervical carcinoma.

CIN means Cervical Intraepithelial Neoplasia

n indicates number of patients

4.5 Management:

Out of the 149 cases of colposcopically suspected CIN I (Table 4.5.2), Loop Electro-surgical Excision Procedure (LEEP) had performed in 63 women and 77 women had treated with cryo therapy. Nine cases were lost without taking any treatment.

Of the 27 cases of moderate dysplasia (Table 4.5.2), 17 subjects underwent LEEP; seven cases had treated with cryo therapy. Three cases were lost without taking any treatment.

Of the nine cases of severe dysplasia/ carcinoma-in-situ (Table 4.5.2), seven had LEEP, and two had treated with hysterectomy.

Follow up colposcopy one year following treatment showed normal appearance of the cervix in 138 cases, persistent CIN I in 16 cases, CIN II in five cases and CIN III in three cases. Nine cases did not come for follow up.

Women with suspected invasive cancer, histopathologically detected carcinoma in-situ and invasive carcinoma advised for indoor admission for further investigations and treatment with surgery, radiotherapy or both.

4.6 Discussion:

The study had initiated with the main objective to consider whether the aided visual inspection could be use as an alternative modality to detect cervical cancerous and precancerous lesions.

Earlier, several studies showed that, visual inspection without aid could not detect early cancers properly. The cancer indicators were cervical ectopy that bleeds on touch, small growths and suspicious unhealthy cervix²⁰. The major drawback was that it missed most of the precancerous conditions. The use

of acetic acid remarkably increased the sensitivity of detecting not only invasive cancer but also the precancerous conditions.²¹

Researchers with VIA is running worldwide to increase the sensitivity and detection rate of precancerous lesions of cervix. In this study, 5593 patients were evaluated. The peak age found within 30-39 years. (Fig 4.5.1) Previous studies correspond well with this study that CIN is more prone to sexually active women.²² Hence, WHO recommends that if a woman can be screened only once in her life time, the best age is between 35 and 45 years.²³

Early epidemiological studies in different countries concluded that the marriage and first delivery at early age are the greatest risk factors for CIN and cervical cancer.^{24,25} This study also showed that almost 91.0% experienced first coitus before the age of 20 years and about 64.0% delivered their first baby between the ages of 15-20 years. Though multiple sexual partners and sexually transmitted infection (STI) are the important factors for CIN,^{26,27} in this study only 17% had extramarital exposure and 02% had history of STI. The use of hormonal contraceptive pills was 54%, which is also considered as a risk factor for CIN.²⁸ This study supports the work of Murthy NS et al. 1990.²⁹ In this study, most of the cases (64%) were from urban area. This may be because of this study was based on urban location and due to urban population are more aware about this problem.

Of the total patients screened (5593), 12% had no symptoms. The presentations were mainly excessive vaginal discharge, inter-menstrual bleeding, lower abdominal pain, dysuria, dyspareunia etc (Fig 4.5.2). All these were non-specific to cervical cancer, which indicates the need of screening for CIN. Speculum examination revealed that 52% cases had apparently healthy

looking cervix. Erosion, ulcer, cauliflower like growth, nodularity expresses the delayed consultation with the doctors or these may be associated with secondary lesion.

In this study, VIA and biopsy correlation was found to be poor for low grade CIN which usually regress in 80% of cases.³⁰ This discrepancy between VIA, colposcopy and histopathology were mostly due to presence of inflammation, metaplasia, ectropion, leukoplakia etc. which showed acetowhite areas but histologically negative for malignancy.

References

1. Sanghvi H. Outcomes Research Study on Cervical Cancer Prevention and Treatment: Results from Ghana, Baltimore, MD, USA: JHPIEGO, **2008**
2. Cronje HS, Cooreman BF, Beyer E, Bam RH, Middlecoté BD, Divall PD. Screening for cervical Neoplasia in a developing country utilizing cytology, cervicography and the acetic acid test. *Int J Gynaecol Obstet* 72:151–157, **2001**
3. Farhat H, Rowshan A B, Kaniz F. Evaluation of Screening Programs for Cancers. *Gynaecological Bangladesh J Obstet Gynaecol*; Vol. 20(1): 29-33, **2005**
4. Mandelblatt, J.S., Lawrence, W.F., Gaffikin, L. et al. Costs and benefits of different strategies to screen for cervical cancer in less-developed countries. *J. Natl. Cancer Inst.*, 94, 1469-1483, **2002**
5. Mimi SA, Hena BSN, Khan MAH and Bhuiyan MSH. Pap's smear: A study on Bangladeshi women in Sylhet. *OMTAJ*. 1(1): 4-6, **2002**
6. Almonte M, Ferreccio C, Winkler JL, Cuzick J, Tsu V, Robles S, Takahashi R, Sasieni P. Cervical screening by visual inspection, HPV testing, liquid-based and conventional cytology in Amazonian Peru. *Int J Cancer* 121: 796–802, **2007**
7. Sankaranarayanan R et al. A critical assessment of screening methods for cervical neoplasia, *International Journal of Gynecology and Obstetrics* 89 (Suppl.2): S4-S12, **2005**
8. Fahey MT, Irwig L, Macaskill P. Meta analysis of Pap test accuracy. *Am J Epidemiol* 141: 680, **1995**
9. Hussain M, Nasir TA, et al. Can VIA replace Pap smear as screening tool

- for cervical for cervical neoplasia: evaluation in 200 cases. *Bang J Pathol* 22(2): 2-9, **2007**
10. Di Bonito L, Falconieri G, Tomasic G, et al. Cervical cytopathology: an evaluation of its accuracy based on cytologic comparison. *Cancer* 72: 3002-3006, **1993**
11. Dai M, Bao YP, Li N, et al. Human papillomavirus infection in Shanxi Province, People's Republic of China: a population-based study. *Br J Cancer* 95: 96-101, **2006**
12. Doh AS, Nkele NN, Achu P, et al. Visual inspection with acetic acid and cytology as screening methods for cervical lesion in Cameroon. *Int J Gynaecol Obstet* 89(2):167-173, **2005**
13. Belinson JL, Pretorius RG, Zhang WH, et al. Cervical cancer screening by simple visual inspection after acetic acid. *American College of Obstetricians and Gynaecologists. Obstet Gynaecol* 98:441-444, **2001**
14. Ghaemmaghani F. Visual inspection with acetic acid as a feasible screening test for cervical Neoplasia in Iran. *Int J Gynecol Cancer* 14(3): 465-469, **2004**
15. Jeronimo J, Oriando M, Jorge H, et al. Visual inspection of the cervix with acetic acid for cervical cancer screening outside of low-resource settings. *Rev Panam Salud Publica/Pan Am J public Health* 17(1), **2005**
16. Denny L. Screen-and-treat approaches for cervical cancer prevention in low resource settings: a randomized controlled trial, *Journal of the American Medical Association* 294(17): 2173-2181, **2005**
17. Goel A, Gandhi G, Batra S, et al. Visual inspection of the cervix with acetic acid for cervical intraepithelial lesions. *International Journal of*

Gynecology and Obstetrics; 88:25-30, **2005**

18. Denny L, Kuhn L, Pollack A, Wright Jr TC. Direct visual inspection for cervical cancer screening: an analysis of factors influencing test performance. *Cancer* 94:1699–1707, **2002**

19. Lawrence, MJ, Wigton, TR, Leonhardt, JG. “Screening for Cervical Neoplasia in an Unselected Rural Guatemalan Population Using Direct Visual Inspection after Acetic Acid Application: A pilot study.” *Journal of Lower Genital Tract Disease*. 9(4). 232-235, **2005**

20. Sehgal A. Screening of uterine cervical cancer using VI-aided and unaided, and colposcopic screening. Presented at the National conference on early detection of cervical cancer-Alternative strategies. Jan 6-8, Delhi, India, **2001**

21. Akinola , Faba'mwo AO, Oshodi YA, et al. Efficacy of visual inspection of the cervix using acetic acid in cervical cancer screening: a comparison with cervical cytology. *Journal of Obstetrics and Gynaecology* 27(7): 703-05, **2007**

22. Cervical cancer in adolescents: screening, evaluation, and management. Committee Opinion No. 463. American College of Obstetricians and Gynecologists. *Obstet Gynecol* 116:469–472, **2010**

23. World Health Organization Comprehensive cervical cancer control: A guide to essential practice 15-191, **2006**

24. De Graaff J, Stolte LAM and Janssens J. Marriage and childbearing in relation to cervical cancer. *Europ J Obstet Gynec Reprod Biol* 7(5): 307- 312, **1977**

25. Brinton LA, Reeves WC, Brenes MM, et al. Parity as a risk factor for

- cervical cancer. *Am J Epidemiol* 130(3): 486-496, **1989**
26. Schiffman M, Kjaer SK.. Natural history of anogenital human papillomavirus infection and neoplasia. *J Natl Cancer Inst Monogr* (31):14-19. Chap 2, **2003**
27. Wright TC Jr, Subbarao S. Human immunodeficiency virus1 expression in the female genital tract in association with cervical inflammation and ulceration. *Am. J. Obstet. Gynecol* 184: 279- 285, **2001**
28. Murthy NS, Mathew A. "Risk factors for pre-cancerous lesions of the cervix". *European Journal of Cancer Prevention* 9 (1): 5-14, **2000**
29. Ylitalo N, Sorensen P, Josefsson A, et al. Smoking and oral contraceptives as risk factors for cervical carcinoma in situ. *Into J Cancer*; 81(3): 357-365, **2000**
30. Bharani B, Phatak S. Role of Colposcopy in evaluation of lower female genital tract in 175 symptomatic women. *J Obstet Gynaecol India* 54:372-5, **2004**

Chapter V

Study No 2

**Visual Inspection of the Uterine Cervix after
application of Acetic Acid in the detection
Cervical Cancer and its Precursors**

5.1 Introduction:

Precise estimation of screening test accuracy including sensitivity and specificity are important to determine policy decision of screening program. Recommendation for optimal frequency screening, management of abnormalities and use of newer technology depend on the screening test property¹

In light of poor results from Pap based screening programs, alternative non cytologic methods for screening such as visual inspection of cervix with acetic acid (VIA) and detection of Human Papillomavirus etc. are already been used in fairly large number of studies.²⁻⁸ Among such alternative cytologic methods, VIA has become very well known for its potentiality, simplicity and low cost and fewer physician visits.⁹⁻¹¹ Such technique can be set up in clinics, health centers, hospitals of both rural and urban areas. This technique needs massive training and practice of medical personnel specially doctors and nurses to pick up actual cervical cancer patients. Accordingly, this study phase was initiated to estimate the performance characteristics (sensitivity, specificity, positive and negative predictive values) of VIA as a primary screening tool for cervical intraepithelial neoplasia (CIN).

5.2 Materials and Methods

During the period from July 2008 to December 2009, 540 women were evaluated who fulfilled the legibility criteria and provided informed consent. Inclusion criteria, exclusion criteria and all the necessary information and clinical data collected for each of the study patients were systematically recorded in a pre designed questionnaire sheet (Appendix III).

Procedure of VIA, colposcopy and histopathology have been described in

details in chapter III.

The criterion standard for this study was cervical biopsy. Colposcopic evaluation and biopsy were done on all patients. Scoring was done using the Reid combined colposcopic index² and a Reid score greater than 2 was considered positive with the exception that when there was a question of metaplasia versus low grade CIN, lesions were classified as low grade. If colposcopy showed no abnormality, biopsies were taken from different quadrants of the cervix. If there were acetowhite areas, biopsies were taken from those suspected areas. All patients who tested positive on screening test underwent Large Loop Excision of the Transformation zone under local anesthesia as an outpatient procedure and the tissue obtained was sent for histopathologic evaluation.

The lesions found mildly dysplastic or worse on histopathologic evaluation were considered true-positive cases. The sensitivity and specificity, the predictive values, the percentages of false-positive results and false-negative results were calculated for VIA and colposcopy with histopathologic results as the gold standard.

5.3 Statistical Analysis

All data were compiled and analyzed manually by preparing a master sheet. Statistical interpretations were done by using Statistical Package for the Social Science (SPSS) program software. Various indices such as sensitivity, specificity, predictive value of positive and predictive value of negative were calculated. P value, < .05 was taken as minimum level of significance. (described in details in chapter III.)

5.4 Study Results:

During the study period from January 2009 to December 2009, total 540 women were evaluated who fulfilled the legibility criteria and provided informed consent.

VIA, Colposcopy and Biopsy Findings:

Out of 540 patients screened, 328(60.74%) were VIA negative, and 212 (39.27%) were VIA positive (Table 5.4.1, Figure 5.4.1). Finding of VIA were evaluated against colposcopic findings and histological reports.

On colposcopy, 340 women (62.96%) were found to have a normal cervix and 200 (37.04%) had a Reid score greater than 2, which was considered positive. Colposcopy yielded normal results in 340 (62.96%) cases, low grade CIN in 138(25.56%) cases, high grade CIN (CIN II and CIN III) in 44(8.15%) cases and cancer in 18(3.33%) cases. (Table 5.4.1 and Figure 5.4.2).

On histology, there were biopsy proven chronic cervicitis with metaplastic changes in 423 (78.33%) cases, CIN I in 66 (12.22 %) cases, CIN II in 25(4.62%) cases, CIN III/ carcinoma-in-situ in 5 (0.93%) cases. Eighteen cases of cervical carcinoma were diagnosed on VIA and colposcopy but ultimately 21 cases of invasive cancer were detected on histology. (Table 5.4.1, and Figure 5.4.3).

Table 5.4.2 and Figure 5.4.4 showed the sensitivity of VIA for biopsy proven CIN I or worse lesion was 74.36% ($p < .001$), specificity 70.45%, positive predictive value 41.04%, and negative predictive value 90.85%. On the other hand, out of 117 biopsies with positive results, 102 detected on colposcopy giving a sensitivity of 87.18% ($p < .001$), specificity 76.83%, positive predictive value 51.0%, and negative predictive value 95.59% respectively.

Screening results of VIA for different grades of CIN are shown in (Table 5.4.3). There were 30 cases of biopsy proven high grade lesions and 28 of these were detected on VIA giving a high sensitivity rate ranging from 92-100% and negative predictive value 100%. Test negative would be reassured that most probably they do not have high-grade lesions or cancer.

Similarly, screening results of colposcopy for different grades of CIN are shown in (Table 5.4.4). The sensitivity of colposcopy in picking up high grade lesions were 96-100% and negative predictive value was 100%.

Table 5.4.1 Percentage detection of different lesions by VIA, Colposcopy and Histopathology.

Screening results	VIA (n=540)	Colposcopy (n=540)	Histopathology (n=540)
Negative/ Normal/	328 (60.74%)	340 (62.96%)	
Chronic cervicitis and metaplasia			423 (78.33 %)
Positive	212 (39.27%)	200 (37.04%)	117 (21.67%)
CIN-I	150 (27.78 %)	138 (25.56%)	66 (12.22 %)
CIN-II	36 (6.67%)	36 (6.67%)	25 (4.62 %)
CIN-III/ Ca-in-situ	08 (1.48%)	08 (1.48 %)	05 (0.93 %)
Carcinoma cervix	18 (3.33%)	18 (3.33%)	21 (3.89 %)

Table 5.4.1 shows, out of 540 patients screened, 328 were VIA negative and 212 were VIA positive. Colposcopy yielded normal results in 340 cases, low grade CIN in 138 cases, high grade CIN in 44 cases and cancer in 18 cases. Of the 200 patients with white epithelium on colposcopy, 98 turned out to be negative on histology. There were biopsy proven chronic cervicitis and metaplastic changes in 423 cases, CIN I in 66 cases, CIN II in 25 cases, CIN III/ carcinoma-in-situ in 5 cases. Eighteen cases of cervical carcinoma were diagnosed on VIA and colposcopy but ultimately 21 cases of invasive cancer were detected on histology.

CIN means Cervical Intraepithelial Neoplasia

n indicates number of patients

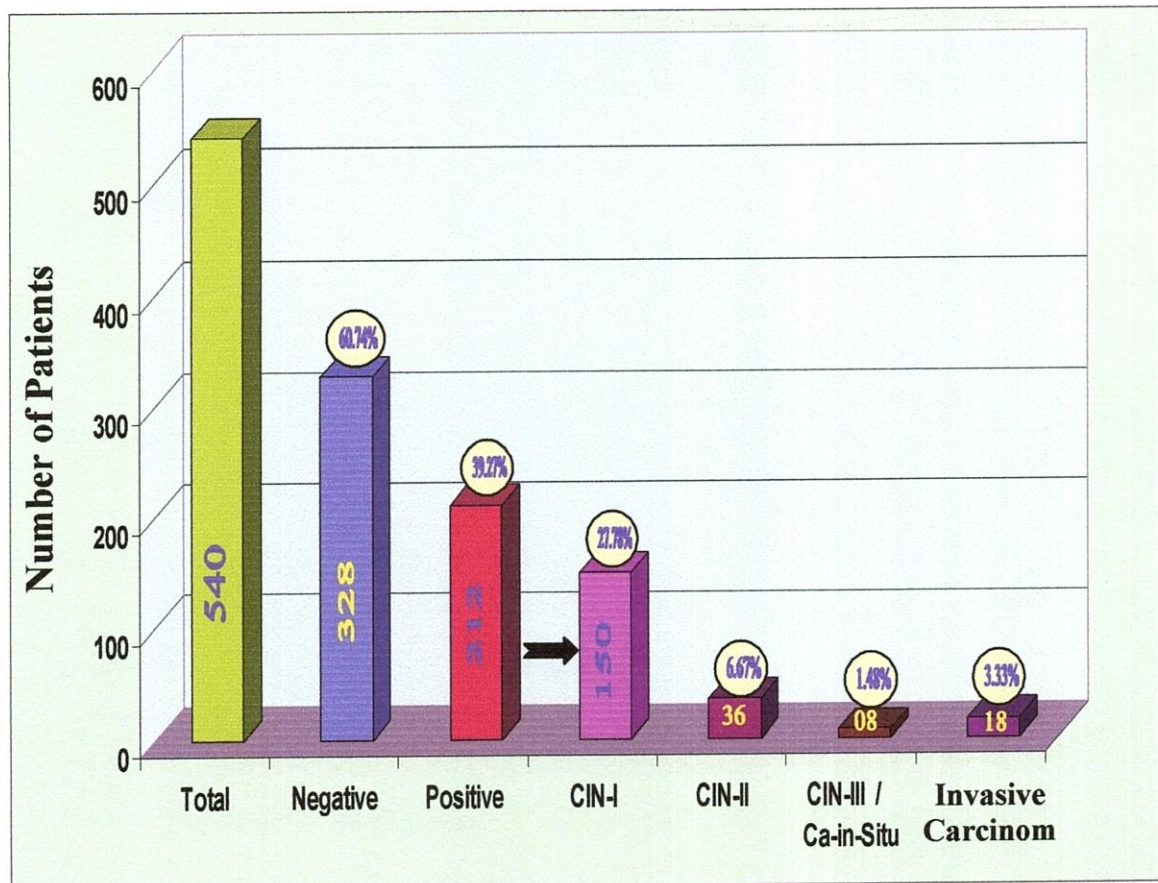


Figure 5.4.1: Percentage detection of different lesions by VIA (n= 540).

Bar diagram shows, out of 540 patients screened, 328 were VIA negative and 212 were VIA positive. Among VIA positive cases, 150 were CIN I, 36 were CIN II, 8 were CIN III/ca-in-situ and 18 cases were invasive carcinoma.

CIN means Cervical Intraepithelial Neoplasia

n indicates number of patients

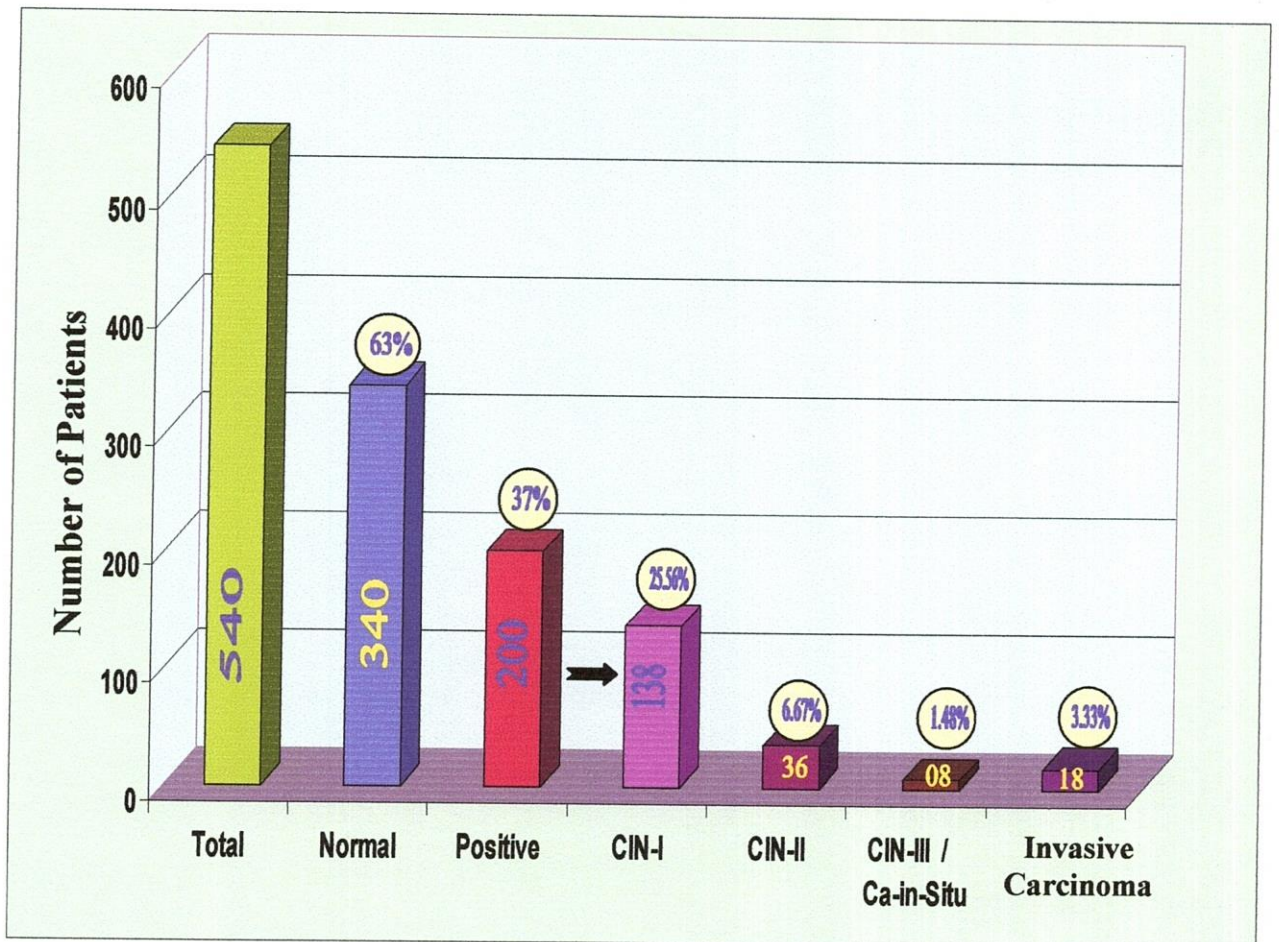


Figure 5.4.2: Percentage detection of different lesions by Colposcopy (n= 540).

Bar diagram-shows colposcopy yielded normal results in 340 cases, low grade CIN in 138 cases, high grade CIN in 44 cases and cancer in 18 cases.

CIN means Cervical Intraepithelial Neoplasia

n indicates number of patients

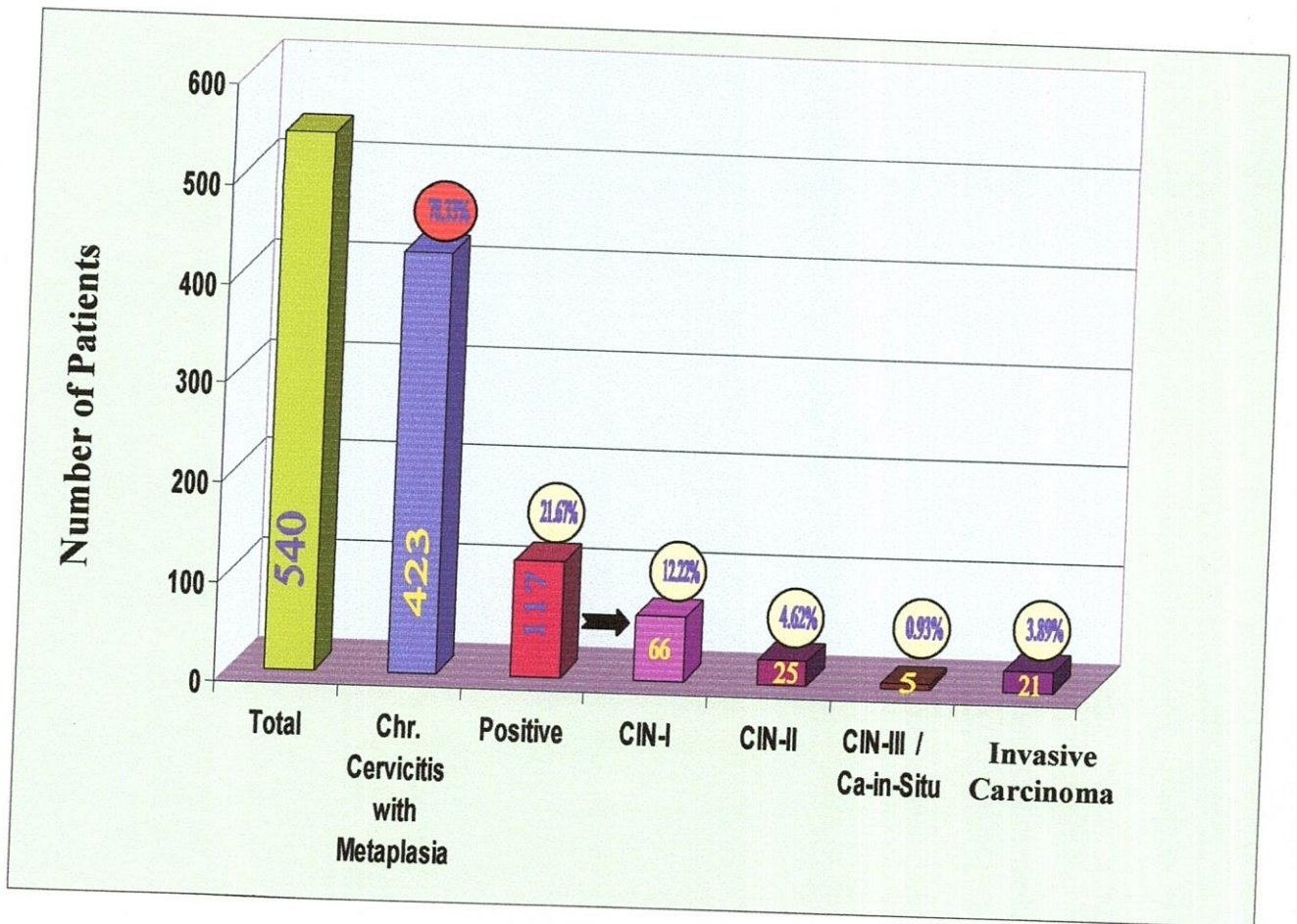


Figure 5.4.3: Percentage detection of different lesions by histopathology (n= 540)

Bar diagram-shows, there are biopsy proven chronic cervicitis and metaplastic changes in 423 cases, CIN I in 66 cases, CIN II in 25 cases, CIN III/ carcinoma-in-situ in 5 cases and 21 cases of invasive cancer were detected on histology.

CIN means Cervical Intraepithelial Neoplasia

n indicates number of patients

Table 5.4.2: Screening results of VIA and Colposcopy

Screening results	VIA	Colposcopy	P value
Sensitivity	87 of 117 (74.36%)	102 of 117 (87.18%)	< .001*
Specificity	298 of 423 (70.45%)	325 of 423 (76.83%)	< .001*
Positive predictive value (PPV)	87 of 212 (41.04%)	102 of 200 (51.0%)	< .001*
Negative predictive value (NPV)	298 of 328 (90.85%)	325 of 340 (95.59%)	< .001*

Table 5.4.2 shows the sensitivity of VIA for biopsy proven CIN I or worse lesion was 74.36% ($p < .001$), specificity 70.45%, positive predictive value 41.04%, and negative predictive value 90.85%. On the other hand, out of 117 biopsies with positive results, 102 detected on colposcopy giving a sensitivity of 87.18% ($p < .001$), specificity 76.83%, positive predictive value 51.0%, and negative predictive value 95.59%.

* Highly significant

Sensitivity: is the tests ability to correctly identify those individuals who truly have the disease among the screened population.

Specificity: is the tests ability to correctly identify those individuals who do not have the disease.

PPV: is the tests ability to correctly identify those individuals who truly have the disease among all those individuals whose tests are positive.

NPV: is the probability that the person with a negative test does not have the disease.

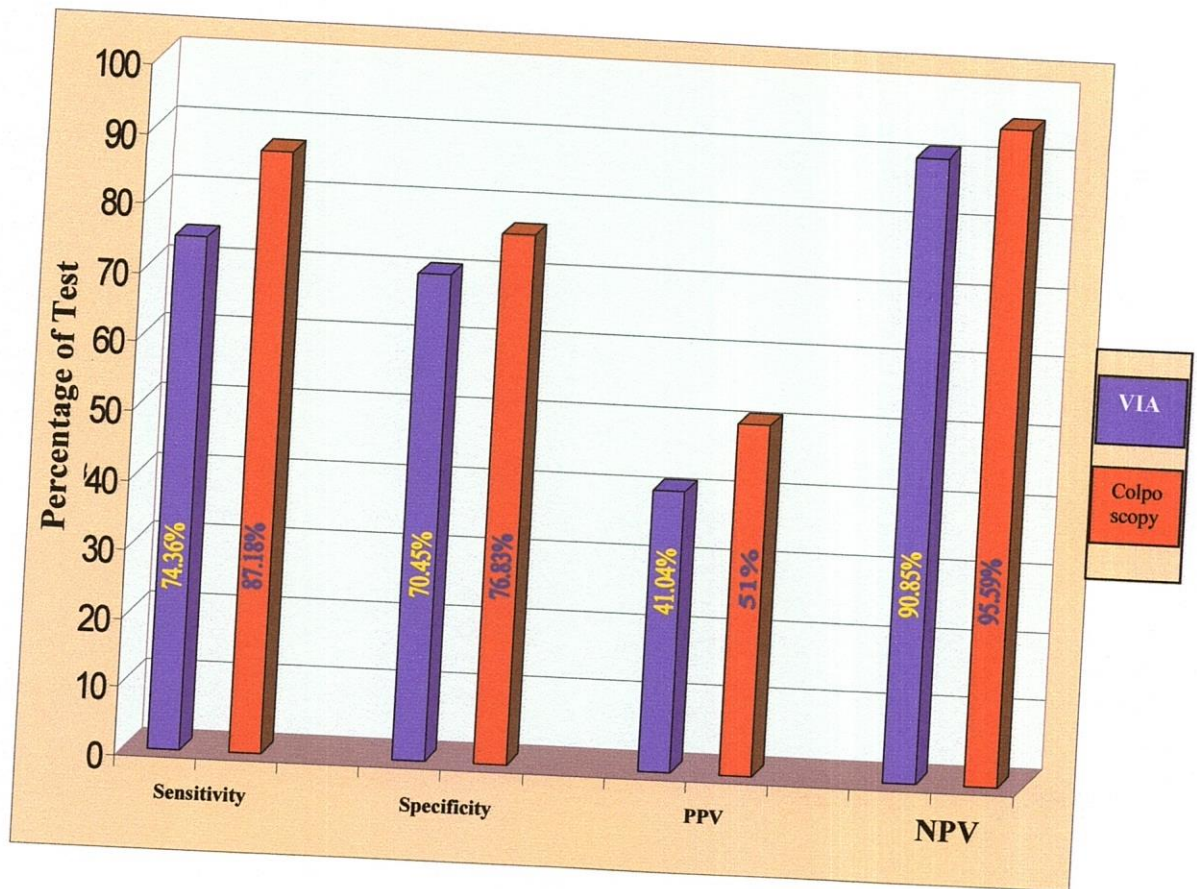


Figure 5.4.4: Screening result of VIA and Colposcopy.

Bar diagram-shows, the sensitivity of VIA for biopsy proven CIN I or worse lesion was 74.36%, specificity 70.45%, positive predictive value 41.04%, and negative predictive value 90.85%. On the other hand, sensitivity of colposcopy was 87.18%, specificity 76.83%, positive predictive value 51.0%, and negative predictive value 95.59%.

PPV means positive predictive value

NPV means negative predictive value

Table 5.4.3: Screening results of VIA for different grades of CIN

Screening results	CIN-I	CIN-II	CIN-III
Sensitivity	50 of 63 (79.37%)	23 of 25 (92.0%)	5 of 5 (100%)
Specificity	315 of 477 (66.04%)	326 of 515 (78.55%)	328 of 535 (61.31%)
Positive predictive value (PPV)	50 of 212 (23.58%)	23 of 212 (10.85%)	5 of 212 (2.36%)
Negative predictive value (NPV)	315 of 328 (95.26%)	326 of 328 (99.39%)	328 of 328 (100%)

Table 5.4.3 [shows screening results of VIA for different grades of CIN. There were 30 cases of biopsy proven high-grade lesions and 28 of these were detected on VIA giving a high sensitivity rate ranging from 92-100% and negative predictive value 100%.

Sensitivity: is the tests ability to correctly identify those individuals who truly have the disease among the screened population.

Specificity: is the tests ability to correctly identify those individuals who do not have the disease.

PPV: is the tests ability to correctly identify those individuals who truly have the disease among all those individuals whose tests are positive.

NPV: is the probability that the person with a negative test does not have the disease.

CIN means Cervical Intraepithelial Neoplasia

Table 5.4.4: Screening results of colposcopy for different grades of CIN

Screening results	CIN-I	CIN-II	CIN-III
Sensitivity	53 of 63 (84.13%)	24 of 25 (96%)	5 of 5 (100%)
Specificity	330 of 477 (69.18%)	339 of 515 (65.83%)	340 of 535 (63.55%)
PPV	53 of 200 (26.5%)	24 of 200 (12%)	5 of 200 (2.5%)
NPV	330 of 340 (97.06%)	339 of 340 (99.71%)	340 of 340 (100%)

Table 5.4.4 shows screening results of colposcopy for different grades of CIN. There were 30 cases of biopsy proven high-grade lesions and 29 of these were detected on colposcopy giving a high sensitivity rate ranging from 96-100% and negative predictive value 100%.

Sensitivity: is the tests ability to correctly identify those individuals who truly have the disease among the screened population.

Specificity: is the tests ability to correctly identify those individuals who do not have the disease.

PPV: is the tests ability to correctly identify those individuals who truly have the disease among all those individuals whose tests are positive.

NPV: is the probability that the person with a negative test does not have the disease.

CIN means Cervical Intraepithelial Neoplasia

5.5 Discussion:

The sensitivity of VIA to detect mild dysplasia or worse, as shown in various studies, ranges from 63% to 77%.³⁻⁷ In this study, the sensitivity of VIA to detect mild dysplasia was 79.37%. (Table 5.4.3). There were 30 cases of biopsy proven high-grade lesions and 28 of these were detected on VIA giving a high sensitivity rate ranging from 92-100% and negative predictive value 100%. (Table 5.4.3). Only two cases of high-grade lesions were missed as they had contact bleeding during VIA procedure.

Since this program was screened a hospital-based symptomatic population, and RMCH is a referral hospital; VIA positivity rate of this study was higher (39.27%) than that found in other studies. If this test had done among general population, it may have showed lower positive rates.

In this study VIA and biopsy correlation is poor for low grade squamous intraepithelial lesion, which resembles normal metaplastic epithelium on VIA as well as on colposcopy but the sensitivity and specificity increase in picking up high grade squamous intraepithelial lesion which is indeed a true cancer precursor and early invasive cancer.

The specificity of VIA was 70.45%, positive predictive value was 41.04% and negative predictive value was 90.85%. The low sensitivity of VIA (74.36%) in this study may be due to light source, which was not halogen-type, and the low specificity may be due to a large number of inflammatory lesions (78.33%), which is responsible for a large number of false positive results. Results of this study were comparable to those of The University of Zimbabwe and Johns Hopkins study (76.7% and 64.1% respectively).⁸ Shankaranarayanan and Mahe (2004)⁹ have published results from a randomized intervention trial in India

comparing VIA to cytology and to HPV DNA testing and found that all three had similar detection rates of CIN-II and CIN-III lesions and the range of sensitivity for VIA was 67-79% and specificity 49-86%.

The findings of this study and results from previous investigations indicate that a major limitation of VIA is its low specificity (less than 80% in most of reported studies.^{10,11,12-16} This, inevitably, leads to high rates of referral and treatment, with the associated potential for increased patients' discomfort and increased numbers of side effects.

The positive predictive value of VIA was lower than that found by Shankaranarayanan et al.¹⁷ This can most likely be explained by the institutional policies, which was required to diagnose any lesion suggesting CIN-I. Shankaranarayanan et al. considered as positive at VIA only those cases with a distinctive and clear acetowhite area, which is more likely to relate to CIN II/III.

It seems from this study that colposcopic magnification associated with marginal improvement in sensitivity without gains in specificity. Nonetheless, VIA can identify most true cases of cervical pre-cancer and cancer. Where large-scale Pap-smear screening is not now available and is not likely to be available consistently in the future, VIA could be a readily available, potentially sustainable means of testing that, when coupled effectively with treatment, could reduce the burden of disease in populations in which the incidence of cervical cancer is high.

References

1. Nanda K, McCrary DC, Myers ER et al. Accuracy of the Papanicolaou test in the screening for and follow up of cervical cytologic abnormalities: a systematic review. *Ann Intern Med* 132: 810-819, **2000**
2. Reid R. A rapid method for improving colposcopic accuracy. *Colposcopic and Gynaecologic Laser Surgery* 3: 139-146, **1987**
3. Syrjänen K, Naud P, Derchain SM, et al. Comparing PAP smear cytology, aided visual inspection, screening colposcopy, cervicography and HPV testing as optional screening tools in Latin America. Study design and baseline data of the LAMS study. *Anticancer Res*, **2005**
4. Sehgal A. Screening of uterine cervical cancer using VI-aided and unaided, and colposcopic screening. Presented at the National conference on early detection of cervical cancer-Alternative strategies. Jan 6-8, Delhi, India, **2001**
5. Denny I, Kuhn I, Pollack A, et al. Evaluation of alternative methods of cervical cancer screening in resource poor settings. *Cancer* 89: 826-833, **2000**
6. Walter, James Hanley. The Canadian Cervical Cancer Screening Trial Study Group. *Engl J Med* 357:1579-1588, October **2007**
7. Gravitt P. New technologies in cervical cancer screening, *Vaccine* 26(Suppl.10): K42-K52, chap. 3, **2008**
8. University of Zimbabwe and JHPIEGO Cervical Cancer Project. Visual Inspection with acetic acid for cervical-cancer screening: test qualities in a primary-care setting. *The Lancet* 353: 869-873, **2003**
9. Shankaranarayanan R, Mahe C. Cervical cancer control in developing world. *Indian J Gynecol Oncol* 4:5-13, **2004**

10. Sherris J, Wittet S, Kleine A, et al. Evidence- based, alternative cervical cancer screening approaches in low- resource setting. *Int. Perspect Sex Report Health*. Sep 35(3): 147-154, **2009**
11. N. Li, J-F Shi, et al. Different cervical cancer screening approaches in a Chinese multicentre study. *British Journal of Cancer* 100: 532-537, **2009**
12. Jahan R A, Rahman F, Badruddoza S M, et al. Role of VIA and Pap smear in the diagnosis of Cervical Precancer: A study of 115 cases. *TAJ* December; vol 22, Number 2, **2009**
13. Lo Sarian, SF Derchain. Evaluation of visual inspection with acetic acid (VIA), Lugol's iodine (VILI), cervical cytology and HPV testing as cervical screening tools in Latin America. *Journal of Medical screening* 12:142-149, **2005**
14. De Vuyst H, Claeys P, Njiru S, et al. Comparison of Pap smear, visual inspection with acetic acid, human Papilomma virus DNA-PCR testing and cervicology. *Int J Gynaecol Obstet*. 89(2): 120-126, **2005**
15. Cronje HS, Parham GP, Cooreman BF, et al. A comparison of four screening methods for cervical neoplasia in a in a developing country. *Am J of Obstet Gynecol* 188: 395-400, **2003**
16. Akinola, Fabamwo AO, Oshodi YA, et al. Efficacy of visual inspection of the cervix using acetic acid in cervical cancer screening: a comparison with cervical cytology. *Journal of Obstetrics and Gynaecology* 27(7): 703-705, **2007**
17. Sankaranarayanan R et al. A critical assessment of screening methods for cervical neoplasia, *International Journal of Gynecology and Obstetrics*; 89(Suppl.2): S4-S12, **2005**

Chapter VI

Study no 3

Evaluation of HPV-DNA Test in Detection of Precancerous and Cancerous Lesions of Cervix

6.1 Introduction:

Of the 190,000 deaths from cervical cancer that occur annually worldwide, the majority take place in developing countries.¹ During the past 20 years, it has been shown that the some carcinogenic, genital human papilloma viruses (HPVs) cause nearly all cases of cervical cancer,² spurring scientists to more completely understand multistage cervical carcinogenesis, and seek HPV-related prevention strategies.

The HPV detection is an objective quality assurance benchmark for cervical cytology.^{3,4} Recently, a hybrid capture technique has been developed to document the presence of the virus in liquid samples obtained from the female genital tract.⁵⁻⁷ Several studies had been carried out in different countries of the world on Pap smear, VIA and HPV-DNA for early detection of cervical carcinoma.^{8,9} This study was also carried out to determine and to compare the effectiveness of HPV DNA testing, cervical cytology and VIA for the detection of precancerous and cancerous lesions of cervix in relation to histopathology.

6.2 Materials and methods

This study was carried out in Gynae Out Patient Department in collaboration with the department of Pathology, Rajshahi Medical College, Rajshahi, during the period from January 2010 to June 2010. 115 patients of 21 to 60 years age group were selected for the study according to enrolment criteria.

Inclusion criteria, exclusion criteria and all other necessary informations and clinical data collected for each of the study patients systematically recorded in a pre designed questionnaire sheet (described in details in Appendix III).

6.3 Materials and Method

Data were collected from the enrolled patients by using a questionnaire. After recording clinical history, cervix was examined on naked eye by cuscus speculum. Paps smear collection and VIA tests were done concurrently. Colposcopic examination was done who were positive in screening tests. In addition, subjects with grossly abnormal cervix even with negative in screening tests were also referred for colposcopy. Samples for IIPV-DNA were taken from the patients referred for colposcopy and biopsies were taken in the same patients. Clinical history, physical findings, Pap smear findings, VIA findings, DNA tests and histological findings were recorded in the pre-designed patient's profile made for the study.

6.3.1 Technique of Pap smear preparation

A clean dry glass slide was numbered. The small end of the wooden Ayer's spatula was placed through the external os high into the canal. The spatula was then rotated clockwise at 360° angle thoroughly for scraping the entire cervical os. The collected samples were spread on two-thirds of clean glass slides, which were immediately dipped into Coplin jar containing fixative (95% ethyl alcohol) for at least 30 minutes. Then the smears were stained by modified Papanicolaou staining method for cytological diagnosis. Cytology was considered positive if any of the following lesions were reported: dysplasia of any grade, carcinoma in situ and invasive cancer. Pap smears were evaluated and diagnosed using the Bethesda system.

6.3.2 Technique of VIA (described in chapter III)

6.3.3 Technique of HPV-DNA test

The samples for HPV DNA testing were obtained by washing the ectocervix, endocervical canal using a special brush by rotating anticlockwise for 3 times and place into HPV collection kit and stored at -20°C until further processing. HPV DNA detection was carried out using a commercially available kit; the Hybrid captures II (Digene Diagnosis HPV Test-IVT) as per the instructions of the manufacturer protocol. The reference investigation (gold standard) for evaluating the accuracy of tests in detecting true positive lesions was histology. Women with a final diagnosis of CIN or carcinoma in situ were considered as true positive cases for the estimation of sensitivity, specificity and predictive values of the screening tests. The estimates for sensitivity, specificity and predictive values were calculated using standard formulae for these tests, using a 2×2 contingency table.

6.4 Statistical analysis

The reference investigation (gold standard) for evaluating the accuracy of tests in detecting true positive lesions was histology. Women with a final diagnosis of CIN or carcinoma in-situ were considered as true positive cases for the estimation of sensitivity, specificity and predictive values of the screening tests. The estimates for sensitivity, specificity and predictive values were calculated using standard formulae for these tests, using a 2×2 contingency table.

6.5 Study Results

During the study period from January 2010 to December 2010, total 115 women were evaluated who fulfilled the legibility criteria and provided informed consent.

Detailed clinical information including pervaginal examinations was recorded. Samples for HPV-DNA were collected (with a special cervical brush) in screening positive cases (VIA positive and Pap smear positive). Colposcopy directed biopsies were taken from the same patients. A total of 50 screening positive cases were subjected to HPV DNA test and histopathology.

VIA test findings

Among 115 patients included in this study subsequent VIA examination showed 30 positive cases and 85 negative cases. Results are shown in Fig 6.5.1.

Pap smear cytological findings

Of the 115 cases, satisfactory smears were obtained in 113 (98.26 %) cases and 2 (1.74 %) smears were unsatisfactory which were included in others diagnostic criteria. On cytological examination 98 (85.22%) were diagnosed as “Inflammatory/ Negative for intraepithelial lesions or malignancy”. One (0.87%) was diagnosed as Atypical squamous cell of undetermined significant (ASCUS), 6 (5.22%) were as Low-grade squamous intraepithelial lesions, 4 (3.48%) were High-grade squamous intraepithelial lesions, 2 (1.74%) were found to be of squamous cell carcinoma. Remaining 4 (3.47%), 2 (1.74%) were unsatisfactory and 2(1.74%) were normal which were included in other diagnostic finding. These are shown in Fig 6.5.5

HPV DNA findings

HPV DNA tests were done in 50 screening positive patients. Of them 19 (38%) were positive and 31(62%) were negative. This is shown in following Fig 6.5.3.

Histopathological findings

Out of 115 cases in the study group, biopsy specimens were taken from 50 patients who were Pap smear positive, VIA positive and clinically suspicious even with negative screening tests. In 65 (54.8%) cases biopsies were not done, of which 63 were normal on screening tests and 2 were refused biopsy. On histopathological examination, 31 (62%) were diagnosed as chronic cervicitis, 9 (18%) as CIN-1, 1 (2%) as CIN-II, 4 (8%) were CIN-III and invasive squamous cell carcinoma was diagnosed in 3 (6%) patients. Two (4%) cases were diagnosed as endocervical polyp and chronic cervicitis with squamous metaplasia, which were included in other diagnostic finding. Table 6.5.1 and Fig 6.5.6 showed the distribution of histopathological diagnosis of 50 cases.

Correlation between histopathology and VIA

Of the total 50 cases in which biopsy were done, VIA tests were positive in 30 cases and negative in 20 cases. Out of 31 histopathologically diagnosed cases of chronic cervicitis, 13 (41.94%) were VIA positive and 18 (58.06%) were VIA negative. Out of 9 CIN-I cases, 8 (88.9%) cases were VIA positive and 1 (11.11%) was VIA negative. All 5 (100%) CIN-II/III cases and all 3 (100%) malignant cases were VIA positive. These are shown in the table 6.5.2.

Correlation between Histopathology and Pap smear cytology

Among the 31 cases of chronic cervicitis, 29 (93.6%) cases were diagnosed as inflammatory cytology, 1 (3.2%) was diagnosed as Atypical squamous cell

of undetermined significant (ASCUS), and 1 as Low-grade squamous intraepithelial lesions (LSIL). Out of 9 cases of CIN-1 lesions, 5 (55.6%) were diagnosed as LSIL and 4 (44.4%) were diagnosed as inflammatory cytology. Out of 5 CIN-II/III cases, 4 (80%) were diagnosed as high-grade squamous intraepithelial lesions (HSIL), 1 as inflammatory cytology. Among the 3 squamous cell carcinoma, 2 were diagnosed as carcinoma and 1 was inflammatory. Table 6.5.3 showed the correlation between histopathology and Pap smear cytology.

Correlation between Histopathology and HPV DNA test

Of the total 50 cases in which biopsy were done HPV DNA tests were positive in 19 cases and negative in 31 cases. Out of 31 histologically diagnosed cases of chronic cervicitis 5 (16.3%) were HPV-DNA positive and 26 (83.87%) were HPV-DNA negative. Out of 9 CIN-I cases 6 (66.37%) were positive and 3 (33.33%) were negative. All 5 (100%) CIN-II and CIN-III were HPV-DNA positive and all 3 (100%) malignant cases were positive (Table 6.5.4)

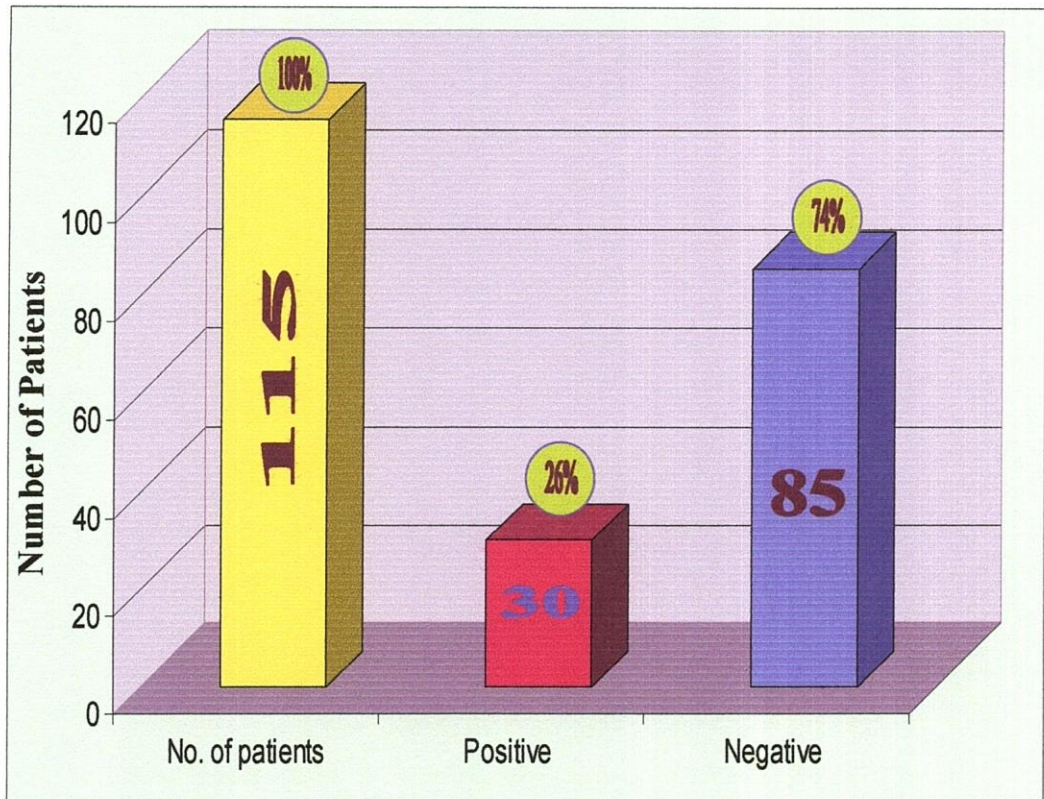


Fig 6.5.1: Screening result of VIA (n=115).

Bar diagram shows, out of 115 patients screened, 30 patients were VIA positive and 85 patients were VIA negative.

n indicates number of patients

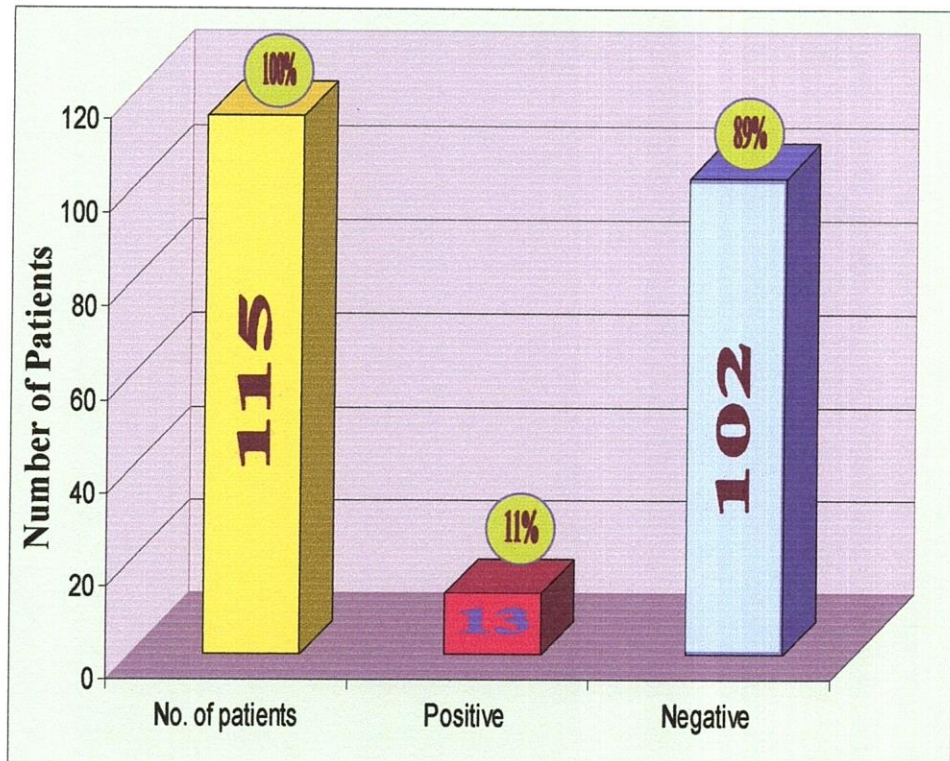


Fig 6.5.2: Screening result of Paps smear cytology (n=115).

Bar diagram shows, out of 115 patients screened, Pap smear was positive in 13 cases and negative in 102 cases.

n indicates number of patients

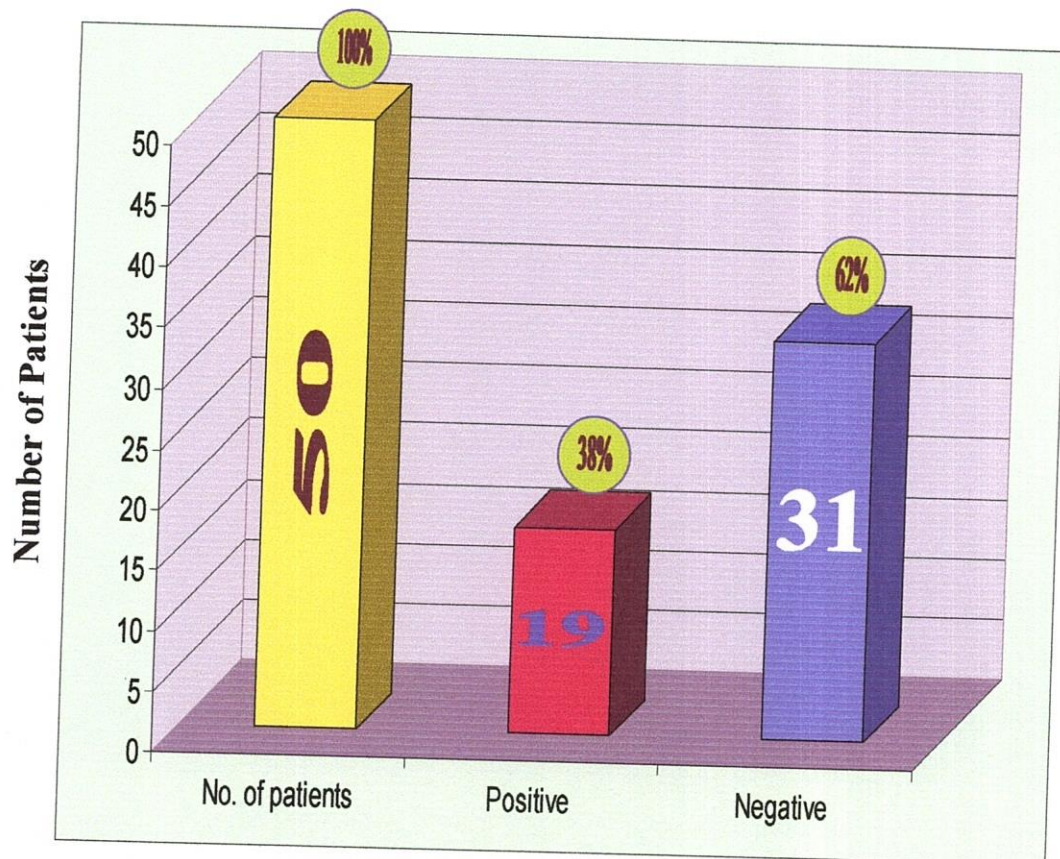


Fig 6.5.3: Screening result of HPV DNA test (n=50)

Bar diagram shows, among 50 screening positive cases, 31 were HPV-DNA negative and 19 were HPV- DNA positive.

n indicates number of patients

Table 6.5.1: Histopathological findings of screening positive cases (n=50)

Histopathological findings	Frequency	Percent
Inflammatory	31	62
CIN-I	09	18
CIN-II	01	2
CIN-III	04	8
Carcinoma	03	6
Endocervical polyp	2	4

Table 6.5.1 shows, out of 50 screening positive biopsy specimens, 31 were diagnosed as chronic cervicitis, 9 as CIN-I, 1 as CIN-II, 4 were CIN-III and invasive squamous cell carcinoma was diagnosed in 3 patients. Two cases were diagnosed as endocervical polyp.

CIN means Cervical Intraepithelial Neoplasia

n indicates number of patients

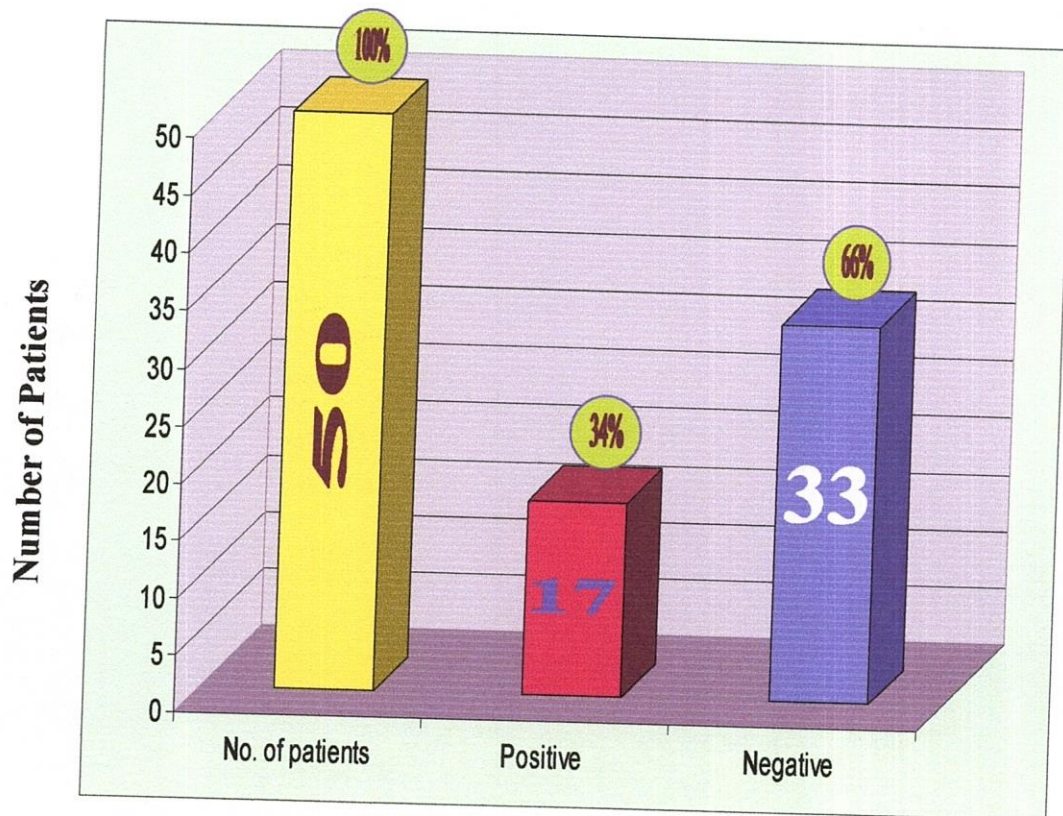


Fig 6.5.4: Histopathological findings of screening positive cases (n= 50)

Bar diagram shows, out of 50 screening positive cases, only 17 cases histologically proved as positive.

n indicates number of patients

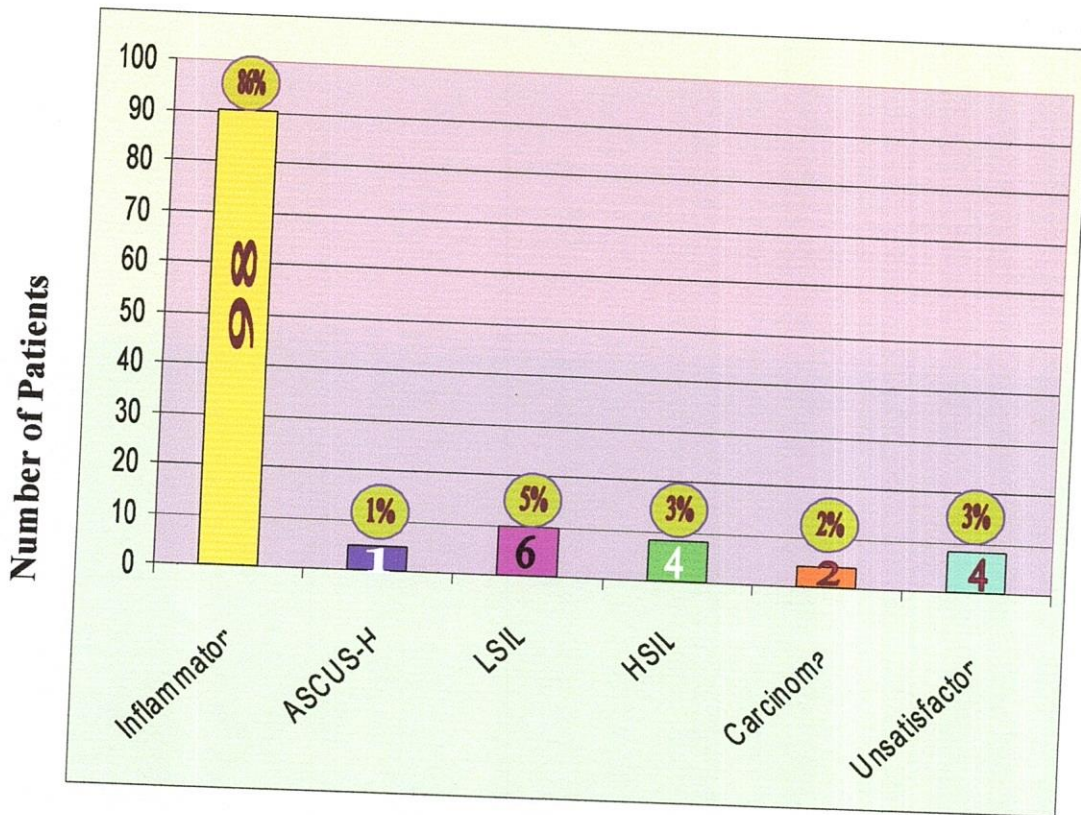


Fig 6.5.5: Pap smear cytological diagnosis of the study patients (n=115)

Bar diagram shows, out of 115 patients screened, 98 cases diagnosed as 'Inflammatory/ Negative for intraepithelial lesions or malignancy' 1 was diagnosed as 'atypical squamous cell of undetermined significant', 6 cases were as Low-grade squamous intraepithelial lesions, and 4 cases were High-grade squamous intraepithelial lesions. 2 cases were found to be squamous cell carcinoma. Remaining 4 had unsatisfactory results.

ASCUS means atypical squamous cell of undetermined significant

LSIL means low-grade squamous intraepithelial lesion

HSIL means high-grade squamous intraepithelial lesion

n indicates number of patients

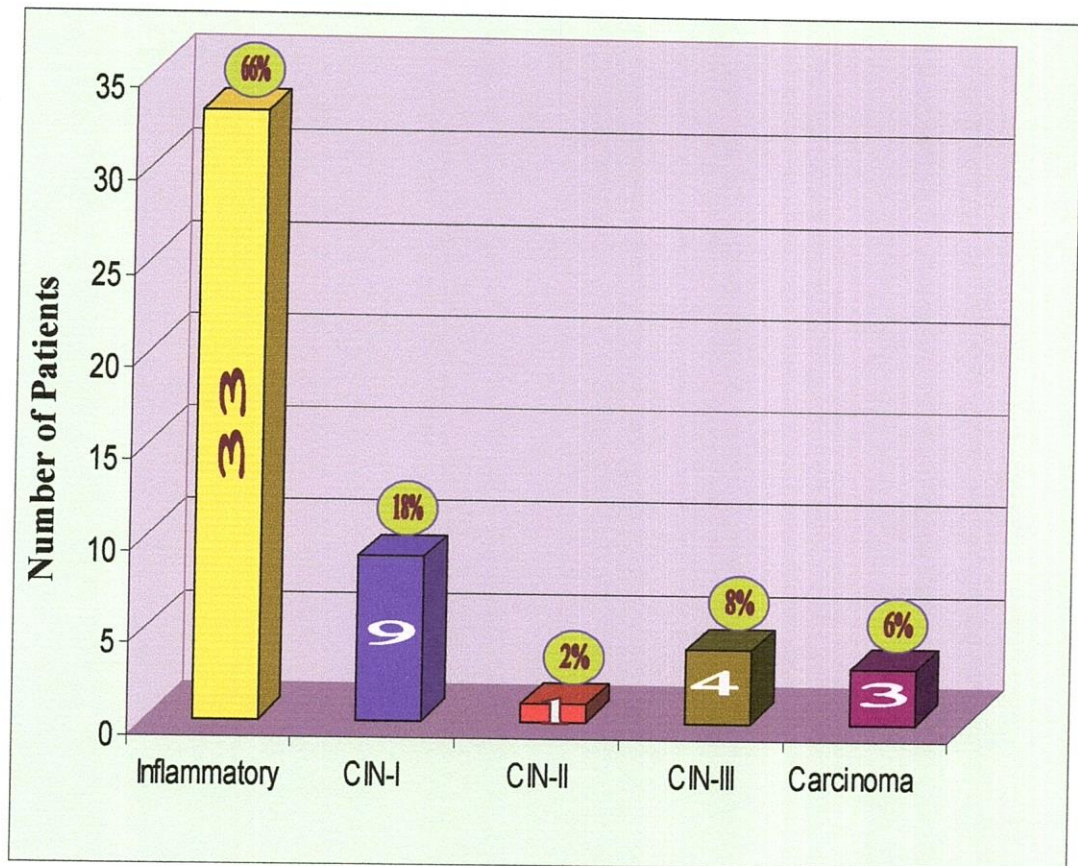


Fig 6.5.6: Histopathological findings of screening positive cases (n=50)

Bar diagram shows, out of 50 biopsy specimens, 33 cases were diagnosed as inflammatory or chronic cervicitis, 9 cases were diagnosed as CIN-I, 1 case was diagnosed as CIN-II, 4 cases were diagnosed as CIN-III and 3 cases were diagnosed as invasive squamous cell carcinoma.

CIN means Cervical Intraepithelial Neoplasia

n indicates number of patients

Table 6.5.2: VIA and its relation to Histopathology (n=50)

Histological diagnosis	No. of patients	VIA test results	
		Positive	Negative
Chronic cervicitis	33	*14 (42.42 %)	***19 (57.58 %)
CIN I	9	**8 (88.89 %)	****1 (11.11 %)
CIN II/III	5	**5 (100 %)	-
Sq. cell carcinoma	3	**3 (100 %)	-
Total	50	30 (60 %)	20(40 %)

Table 6.5.2: shows, out of total 50 cases in which biopsy were taken, VIA tests were positive in 30 cases and negative in 20 cases. Out of 33 histologically diagnosed cases of chronic cervicitis, 14 were VIA positive and 19 were VIA negative. Out of 9 CIN-I cases, 8 cases were VIA positive and 1 was VIA negative. All 5 cases of CIN-II/III and all 3 malignant cases were VIA positive.

* False positive = 14 (Disease negative but test positive)

** True positive = 16 (Both test positive and disease positive)

*** True negative = 19 (Both test negative and disease negative)

**** False negative = 1 (Disease positive but test negative)

CIN means Cervical Intraepithelial Neoplasia

n indicates number of patients

Table 6.5.3: Pap smear cytology and its relation to Histopathology (n=50)

Histological diagnosis	No. of patients	Pap smear cytological diagnosis				
		Inflammatory cytology	ASCUS	LSIL/ CINI	HSIL/ CIN-II/III	Sq. cell ca
Chronic cervicitis	33	***31(96 %)	*1(3.2%)	*1 (3.2%)	-	-
CIN-I	9	****4(44.4%)	-	**5 (55.6%)	-	-
CIN-II/III	5	****1 (20%)	-	-	**4 (80%)	-
Invasive Sq. cell carcinoma	3	****1(33.3%)	-	-	-	**2 (66.7%)
Total	50	37	1	6	4	2

Table 6.5.3: shows on the histologic basis, among the 33 cases of chronic cervicitis, 31 cases were correctly diagnosed cytologically as inflammatory cytology or negative for intraepithelial lesions. Out of the 9 CIN-I lesions, 4 cases were diagnosed as LSIL and out of 5 CIN-II/III 4 cases were diagnosed correctly as HSIL by cytology. Among 3 the cases of squamous cell carcinoma, 2 were correctly diagnosed by Pap smear cytology.

* False positive = 2 (Disease negative but test positive)

** True positive = 16 (Both test positive and disease positive)

*** True negative = 19 (Both test negative and disease negative)

**** False negative = 1 (Disease positive but test negative)

CIN means Cervical Intraepithelial Neoplasia

n indicates number of patients

Table 6.5.4: HPV DNA test and its relation of Histopathology (n=50)

Histopathological diagnosis	No. of patients	HPV DNA Test Results	
		Positive	Negative
Chronic cervicitis	33	*5(15.15 (%))	***28 (84.85 (%))
CIN I	9	**6(66.67 (%))	****3 (33.33 (%))
CIN II	1	**1(100 (%))	-
CIN III	4	**4(100 (%))	-
Sq. cell carcinoma	3	**3(100 (%))	-
Total	50	19 (38 %)	31(62 %)

Table 6.5.4 shows, among 50 screening positive cases, 19 were HPV-DNA positive and 31 were HPV DNA negative. Histologically, 5 cases of chronic cervicitis, 6 cases of CIN-I and all cases of CIN-II/III and carcinoma showed HPV DNA test positive.

- *False Positive = 5 (Disease negative but test positive)
- **True positive = 16 (Both test positive and disease positive)
- ***True negative = 19 (Both test negative and disease negative)
- ****False negative = 1 (Disease positive but test negative)

CIN means Cervical Intraepithelial Neoplasia

n indicates number of patients

Table 6.5.5: Statistical analysis of VIA, Pap smear cytology and HPV DNA test

Diagnostic Methods	True positive	True negative	False positive	False negative	Sensitivity (%)	Specificity (%)	Positive predictive value PPV (%)	Negative predictive value NPV (%)	Accuracy (%)
VIA	16	19	14	1	94.11	57.57	53.33	95.00	70.00
Pap	11	31	2	6	64.71	93.94	84.62	83.78	84.00
HPV	14	28	5	3	82.35	85.71	73.68	90.91	84.62

Table 6.5.5: shows, VIA test was accurate in 70% of cases with 94.1% (16 of 17) true positive, 5.9 % (1 of 17) false negative, 57.6 % (19 of 33) true negative and 57.6 % (14 of 33) false positive cases. Pap smear cytology was diagnostically accurate in 84% of the cases with 64.7% (11 of 17) true positive , 35.3% (6 of 17) false negative, 93.9% (31 of 33) true negative and 6% (2 of 33) false positive case. HPV DNA test was diagnostically accurate in 84.62% of the cases with 83.35% (14 of 17) true positive, 17.65% (3 of 17) false negative, 84.84% (28 of 33) true negative, 15.15% (5 of 33) false positive. The sensitivity, specificity, positive predictive value, negative predictive value for the HPV DNA were 82.35%, 84.85%, 73.68%, 90.32%, pap smear were 64.7%, 93.94%, 84.62%, 83.78% and for the VIA test were 94.11%, 57.57%, 53.53% 95% respectively.

Discussion

This study has addressed the test performances of three screening approaches (VIA, Pap smear and HPV DNA test) to detect cervical neoplasm. To evaluate the success of the present study; the findings were compared with observations by others.

To evaluate the success of the present study; the findings were compared with observations by others. From the results of this study it is noted that VIA test is superior to Pap smear and HPV-DNA test in sensitivity (94.11%) that is VIA can more accurately identified the CIN/cancer patients and the sensitivity of VIA (94.11%) was higher than that observed from other cross sectional studies conducted in Zimbabwe, China, India and Latin America which used nursing, paramedical and medical background.¹⁰⁻¹⁶ However, the specificity of VIA (57.57%) was lower in this study as compared to these reports. Pap smear is superior to VIA and HPV DNA test in specificity (84%) that is it can more accurately identified the truly well peoples. HPV DNA test is more sensitive than the Pap smear (less likely to produce false negative results), but less specific (more likely to produce false positive results) and detected all cases (100%) of high grade lesions (CIN II and III) and carcinoma.

In this study the positive predictive value and negative predictive value for VIA were 53.53% and 95% respectively. These values were also closely similar to those of Hussain M (2007).¹⁷ The negative predictive value for VIA (95%) in this study reflects a chance of missing CIN/cancer was 5%. On the other hand negative predictive value for Pap smear (83.78%) reflects that probability of not having CIN/cancer was 83.78% and the chance of missing CIN/cancer was

The 16.22%. This rate is very high and not suitable for cancer screening. Positive predictive value and negative predictive value for HPV DNA of this study were 73.68% and 90.32% respectively. These values differ with those of Israt T (2006).¹⁸

Since more than 99% of invasive cervical cancers worldwide contain HPV, some researchers recommend that HPV testing be done together with routine cervical screening. But, given the prevalence of HPV (around 80% infection history among the sexually active population),¹⁹ others suggest that routine HPV testing would cause undue alarm to carriers, more unnecessary follow-up testing and treatment. HPV testing along with cytology significantly increases the cost of screening. Moreover, it is more expensive and time-consuming than other screening tests, and it requires a sophisticated laboratory infrastructure. Experience to date in low-resource settings suggests that these factors, combined with potential challenges in collecting specimens, limit the applicability of the currently marketed test. Until it is possible to produce a test with similar performance that is simpler to use, less expensive and more robust in typical developing-country conditions, HPV DNA testing is unlikely to reach its full potential in reducing cervical cancer. None study showed that the screening tests such as Pap, VIA and HPV-DNA test separately were suitable for the diagnosis of cervical lesions.

References

1. Samuel Ratnam, Eduardo L. Franco and Alex Ferenczy. Human Papillomavirus Testing for Primary Screening of Cervical Cancer Precursors. *Cancer Epidemiol Biomarkers Prev* 9: 945-951, **2000**
2. Almonte M, Ferreccio C, Winkler JL, et al. Cervical screening by visual inspection, HPV testing, liquid-based and conventional cytology in Amazonian Peru. *Int J Cancer* 121: 796–802, **2007**
3. Schiffman M, Castle E.P. Human papilloma virus epidemiology and public health. *Arch Pathol Lab Med* 127: 930- 931, **2003**
4. Gravitt P. Chapter 3: new technologies in cervical cancer screening, *Vaccine* 26 (Suppl.10): K42-K52, **2008**
5. Castle PE, Solomon D, Cosset M. Human papilloma virus genotype specificity of hybrid Capture2. *J Clin Microbiol.* 46(8): 2595-2604, **2008**
6. Koss LG, Melamed. *Koss's Diagnostic Cytology and Its Histopathologic Bases.* 5th edition. A wolters Kluwer Company: pp.293, **2006**
7. Kuhn L, Denny L, Pollack A, Lorincz A, Richart RM, Wright TG. Human Papilloma virus DNA testing for cervical cancer screening in low resource settings. *J Natl Cancer Inst.* 92: 818-825, **2000**
8. Qiao YL, Sellors JW, Eder PS, et al. A new HPV-DNA test for cervical cancer screening in developing regions: a cross sectional study of clinical accuracy in rural China. *Lancet Oncol* 9: 929-36, **2008**
9. Jeronimo J, Castle PE, Herrero R, Burk RD, Schiffman M. HPV testing and visual inspection for cervical cancer screening in resource-poor regions. *Int J Gynaecol Obstet* 83(3): 311–313, **2003**
10. University of Zimbabwe and JHPIEGO Cervical Cancer Project. Visual Inspection with acetic acid for cervical- cancer screening: test qualities

in a primary care setting. *The Lancet* 353: 869-873, **2003**

11. N. Li, J-F Shi. Different cervical cancer screening approaches in a Chinese multicentre study. *British Journal of Cancer* 100: 532-537, **2009**

12. Belinson J, Qiao YL, Pretorius R, et al. Shanxi Province Cervical Cancer Screening Study: a cross-sectional comparative trial of multiple techniques to detect cervical neoplasia. *Gynecol Oncol* 83: 439-444, **2001**

13. Cronje HS, Parham GP, Cooreman BF, et al. A comparison of four screening methods for cervical neoplasia in a in a developing country. *Am J of Obstet Gynecol* 188: 395-400, **2003**

14. Sankaranarayanan R, Nene BM, Shastri SS, *et. al* . HPV screening for cervical cancer in rural India. *N Engl J Med* 360: 1385-1394, **2009**

15. R A Jahan, F Rahman, S M Badruddoza, et al. Role of VIA and Pap smear in the diagnosis of Cervical Precancer: A study of 115 cases. *TAJ* vol 22, Number 2, **2009**

16. Lo Sarian, SF Derchain. Evaluation of visual inspection with acetic acid (VIA), Lugol's iodine (VILI), cervical cytology and HPV testing as cervical screening tools in Latin American *Journal of Medical screening* 12: 42-149, **2005**

17. Hussain M, Nasir TA. Can VIA replace Pap smear as screening tool for cervical neoplasia: evaluation in 200 cases. *Bang J Pathol.* 22 (2): 2-9, **2007**

18. Israt T. Study on HPV-DNA Test and Conventional Pap test for Identification of Cervical Intraepithelial Lesions and Cancer. MD Thesis, BSMMU, Dhaka, **2006**

19. Belinson J, Qiao YL, Pretorius R, et al. ShanxiProvince cervical cancer screening study: a cross-sectional comparative trial of multiple techniques to detect cervical neoplasia. *Gynecol Oncol*; 83:439-444, **2001**

Chapter VII

General Discussion and conclusion

The work embodied in this thesis is the screening of cervical cancer with visual inspection after acetic acid among women in RMCH through three phases of the study.

In first phase of this study the performance of VIA in the detection of precancerous and cancerous lesion of the cervix have been evaluated.

Among 5593 patients, the peak age was found within 30-39 years. (Fig 4.5.1)

Previous studies correspond well with this study that CIN is more prone to sexually active women.¹ Hence, WHO recommends that if a woman can be screened only once in her life time, the best age is between 35 and 45 years.²

Early epidemiological studies in different countries concluded that the marriage and first delivery at early age are the greatest risk factors for CIN and cervical cancer.^{3,4} This study also showed that almost 91.0% experienced first coitus before the age of 20 years and about 64.0% delivered their first baby between the ages of 15-20 years. Though multiple sexual partners and sexually transmitted infection are the important factors for CIN,^{5,6} in this study only 17% had extramarital exposure and 02% had history of sexually transmitted infection. The use of hormonal contraceptive pills was 54%, which is also considered as a risk factor for CIN⁷ and supports the work of Murthy NS et al. 1990.⁶ In this study, most of the cases (64%) were from urban area. This may be because of this study was based on urban location and due to urban population are more aware about this problem.

Earlier, several studies showed, unaided visual inspection could detect about 60% of women with early cancers. The cancer indicators were cervical ectopy that bleeds on touch, small growths and suspicious unhealthy cervix.⁸⁻¹⁰ The major drawback was that it missed most of the precancerous conditions. In this study, the main complaints were intermenstrual bleeding, post coital bleeding, irregular vaginal bleeding, excessive dirty brown or whitish discharge

and lower abdominal pain etc (Fig 4.5.2). All these were non-specific to cervical cancer, which indicates the need of screening for CIN. The use of acetic acid remarkably increased the sensitivity of detecting not only invasive cancer but also the precancerous conditions.^{11,12}

In this study, VIA and biopsy correlation is found to be poor for low grade CIN which usually regress in 80% of cases.¹³ This discrepancy between VIA, colposcopy and histopathology were mostly due to presence of inflammation, metaplasia, ectropion, leukoplakia etc. which showed acetowhite areas but histologically negative for malignancy. So colposcopic evaluation is complementary for avoiding false positive cases.^{14,15}

In second phase of study, screening results of VIA and colposcopy for different grades of CIN among 540 patients were evaluated.

In this study, the sensitivity of VIA to detect mild dysplasia was 79.37%. (Table 5.4.3). The sensitivity of VIA to detect mild dysplasia or worse lesion of cervix, as shown in various studies, ranged from 63% to 77%.¹⁶⁻¹⁸ There were 30 cases of biopsy proven high-grade lesions and 28 of these were detected on VIA giving a high sensitivity rate ranging from 92-100% and negative predictive value 100% (Table 5.4.3). Since this screening program was on hospital-based symptomatic population, VIA positivity rate was higher (39.27%) than that found in other studies. If this test had done among general population, may have obtained lower positive rates. The findings of this study showed that VIA could identify most of the true cases of cervical precancer and cancer. But results from previous investigations indicate that a major limitation of VIA is its low specificity (less than 80%) in most of reported studies.¹⁹⁻²² This, inevitably, leads to high rates of referral and treatment, with the associated potential for increased patients' discomfort and increased numbers of side effects. The low sensitivity of VIA in this study could be due to light source, which was not

halogen-type, and the low specificity could be due to a large number of inflammatory lesions (78.33%), which is responsible for a large number of false positive results. Our results are comparable to those of The University of Zimbabwe and Johns Hopkins study (76.7% and 64.1% respectively).^{23,24} Shankaranarayanan and Mahe (2004)²⁵ have published results from a randomized intervention trial in India comparing VIA to cytology and to HPV DNA testing and found that all three had similar detection rates of CIN-II and CIN-III lesions and the range of sensitivity for VIA was 67-79% and specificity 49-86% which also correlates our study.

In this study the positive predictive value for VIA was lower than that found by Shankaranarayanan et al.²⁶ This can most likely be explained by the institutional policies, which was required to diagnose any lesion suggesting of CIN I. Shankaranarayanan et al. considered as positive at VIA only those cases with a distinctive and clear acetowhite area, which is more likely to be related to CIN II/III.

Evaluation of HPV DNA test in the detection of precancerous and cancerous lesion of the cervix have been performed in third phase of the study.

In this study, the sensitivity of VIA (94.11%) was higher than that observed from other cross sectional studies conducted in Zimbabwe, China, India and Latin America which used nursing, paramedical and medical background.²⁷⁻³³ However, the specificity of VIA (57.57%) was lower in as compared to these reports. Though the sensitivity of Pap smear (64.71%) was clearly inferior to that of VIA (94.11%), the specificity was significantly greater (93.94%) than that of VIA (57.57%).

On evaluation of results of different studies including this one it is observed that VIA test is superior to Pap test and HPV-DNA test in sensitivity that is VIA can more accurately identify the CIN/cancer patients and Pap smear is superior to VIA and HPV DNA test in specificity that is it can more accurately identify the truly well peoples and HPV-DNA has strong association in high grade lesions of the cervix.³⁴⁻³⁷ VIA and HPV-DNA tests detected all cases of high grade lesions (CIN II and III) and carcinoma.

The human and financial resources available in a country determine what screening tests are to be performed and who will perform them. Precise estimates of screening test accuracy including sensitivity and specificity are also important to determine policy decision of screening program. The high cost of screening and the resulting unnecessary follow-up procedures have led international health agencies such as the WHO and the Union International Centre for Cancer to recommend increasing screening intervals from annual to every 3 years.³⁸⁻⁴¹

The reported findings of different studies suggested that VIA is a simple, readily available, potentially sustainable real time objective test that, when coupled effectively with treatment, could reduce the burden of disease in populations in which the incidence of cervical cancer is high. It is likely that standardized training, development of quality control procedures, and uniform definitions of VIA test outcomes may contribute to some improvement of the specificity of visual inspection based screening approaches without substantially lowering sensitivity.

Before addressing the implications of this study, it is important that to consider its limitations. The limitation of this study was that it did not reflect the

susceptible women of whole community who should be screened, as the centre still using an opportunistic approach. That is, it is only women who have already come to hospitals or clinics for other problems were advised to go for a VIA test. So long-term efficacy of VIA based screening in reducing the cervical cancer burden remains to be demonstrated. Results from completed and ongoing studies will further clarify the role of VIA and related strategies.

Despite the use of available resources, infrastructure and guidelines for cervical cancer screening implementation in resource limited areas, community participation and non-compliance remain the major obstacles to successful reduction in cervical cancer mortality in this population.

So in conclusion, we hope, our gynecologists, pathologists, administrators, supporting agencies and concerned peoples should take the challenge to cut down the sufferings of our females and families from cervical cancer and to have a steady step towards millennium of good health.

References

1. Cervical cancer in adolescents: screening, evaluation, and management. Committee Opinion No. 463. American College of Obstetricians and Gynecologists. *Obstet Gynecol* 116:469–472, **2010**
2. World Health Organization, comprehensive cervical cancer control: A guide to essential practice 15-191, **2006**.
3. De Graaff J, Stolte LAM and Janssens J. Marriage and childbearing in relation to cervical cancer. *Europ J Obstet Gynec Reprod Biol* 7(5): 307-312, **1977**
4. Cervical intraepithelial neoplasia: Overview, Risk Factors. From Wikipedia, the free encyclopedia. Last modified on 3 May, **2012**
5. Biswas LN, Manna B, Maiti PK and Sengupta S. Sexual risk factors for cervical cancer among Rural Indian women: A case-control study. *International Journal of Epidemiology* 26 (3): 492-495, **1997**
6. Murthy NS, Mathew A. "Risk factors for pre-cancerous lesions of the cervix". *European Journal of Cancer Prevention* 9 (1): 5–14, **2000**
7. Castellsague X, Munoz N. Cofactors in Human papilloma virus carcinogenesis- role of parity, oral contraceptives and tobacco smoking. *Journal of the Cancer Institute Monograph* 31: 20-28, **2003**
8. Sehgal A. Screening of uterine cervical cancer using VI-aided and unaided, and colposcopic screening. Presented at the National conference on early detection of cervical cancer-Alternative strategies. Jan 6-8, Delhi, india, **2001**
9. Akinola OI, Faba'mwo AO. Oshodi YA, et al. Efficacy of visual inspection of the cervix using acetic acid in cervical cancer screening: a comparison with

- cervical cytology. *Journal of Obstetrics and Gynaecology* 27(7):703-05, **2007**
10. Sherris J, Wittet S, Kleine A, et al. Evidence- based, alternative cervical cancer screening approaches in low- resource setting. *Int. Perspect Sex Report Health* 35(3): 147-154, **2009**
11. Sankaranarayanan R, Basu P, Wesley RS, *et al.* Accuracy of visual screening for cervical neoplasia: results from an IARC multicentre study in India and Africa. *Int J Cancer* 110: 907–913, **2004**
12. Ghaemmaghani F. Visual inspection with acetic acid as a feasible screening test for cervical neoplasia in Iran. *Int J Gynecol Cancer* 14(3):465- 469, **2004**
13. Denny L, Kuhn L, Pollack A, Wright Jr TC. Direct visual inspection for cervical cancer screening: an analysis of factors influencing test performance. *Cancer* 94:1699–1707, **2002**
14. Singer A, Monaghan JM. Lower Genital Tract Precancer Colposcopy, Pathology and Treatment. 2nd Edition, Blackwell Science, Oxford 70- 120, **2000**
15. Johnson C. Conventional cytology. In: Apgar BS, Brotzman GL, Spitzer M (eds). *Colposcopy principles and practice. An integrated Textbook and atlas.* Philadelphia, W.B. Saunders Company 52-56, **2002**
16. Lawrence MJ, Wigton TR, Leonhardt JG. “Screening for Cervical Neoplasia in an unselected rural Guatemalan Population Using Direct Visual Inspection after Acetic acid application: A pilot study.” *Journal of Lower Genital Tract Disease* 9(4): 232-235, **2005**
17. Goel A, Gandhi G. Batra S. et al. Visual inspection of the cervix with acetic acid for cervical intraepithelial lesions. *International Journal of Gynecology and Obstetrics* 8: 25-30, **2005**

18. Singh Kavita N, More Shefali. Visual inspection of cervix with acetic acid (VIA) in early diagnosis cervical intraepithelial neoplasia (CIN) and early cancer cervix. *J Obstet Gynecol India* vol. 60, No.1, 55-60, **2010**
19. Rodriguez-Reyes ER, Cerda-Flores RM, Quinonez-Perez JM, et al. Acetic acid test: a promising screening test for early detection of cervical cancer. *Anal Quant Cytol Histol* 24:134–136, **2002**
20. Snijders PJ, Steenbergen RD, Heideman DA, Meijer CJ "HPV-mediated cervical carcinogenesis: concepts and clinical implications." *J. Pathol*; 208 (2): 152–164, **2006**
21. Garrett ES, Eaton WW, Zeger SL. Methods for evaluating the performance of diagnostic tests in the absence of a gold standard: a latent class model approach. *Stat Med* 21:1289–1307, **2000**
22. Goel A, Gandhi G. Batra S. et al. Visual inspection of the cervix with acetic acid for cervical intraepithelial lesions. *International Journal of Gynecology and Obstetrics* 8: 25-30, **2005**
23. University of Zimbabwe and JHPIEGO Cervical Cancer Project Visual Inspection with acetic acid for cervical-cancer screening: test qualities in a primary-care setting. *The Lancet* 353: 869-873, **2003**
24. Shankaranarayanan R, Mahe C. Cervical cancer control in developing world. *Indian J Gynecol Oncol* 4: 5-13, **2004**
25. Sankaranarayanan R, Basu P, Wesley RS, et al. Accuracy of visual screening for cervical neoplasia: results from an IARC multicentre study in India and Africa. *Int J Cancer* 110: 907–913, **2004**

26. Wright TC Jr., Schiffman M., Solomon D. et al. Interim guidance for the use of human papillomavirus DNA testing as an adjunct to cervical cytology for screening. *Obstet Gynecol* 103(2):304–309, **2004**
27. Jeronimo J, Castle PE, Herrero R, Burk RD, Schiffman M. HPV testing and visual inspection for cervical cancer screening in resource-poor regions. *Int J Gynaecol Obstet* 83(3): 311–313, **2003**
28. Qiao YL, Sellors JW, Eder PS, et al. A new HPV-DNA test for cervical cancer screening in developing regions: a cross sectional study of clinical accuracy in rural China. *Lancet Oncol* 9: 929-936, **2008**
29. Belinson J, Qiao YL, Pretorius R, et al. Shanxi Province cervical cancer screening study: a cross-sectional comparative trial of multiple techniques to detect cervical neoplasia. *Gynecol Oncol* 83:439–444, **2001**
30. Lo Sarian, SF Derchain. Evaluation of visual inspection with acetic acid (VIA), Lugol's iodine (VILI), cervical cytology and HPV testing as cervical screening tools in Latin American *Journal of Medical screening* 12: 42-149, **2005**
31. Bhatla N, Mukhopadhyay A, Kriplani A, et a. Evaluation of adjunctive tests for cervical cancer screening in low resource settings. *Indian J Cancer* 44(2): 51-5, **2007**
32. N. Li, J-F Shi. Different cervical cancer screening approaches in a Chinese multicentre study. *British Journal of Cancer* 100: 532-537, **2009**
33. Schiffman M and Wacholder S, From India to the world –a better way to prevent cervical cancer, *New England Journal of Medicine* 360: 1453-1455, **2009**
34. Wasti S, Ahmed W, Jafri A, et al. Analysis of cervical smear in a Muslim population. *Ann Saudi Med* 24(3): 189-192, **2004**

35. Syrjänen K, Naud P, Derchain SM, et al. Comparing PAP smear cytology, aided visual inspection, screening colposcopy, cervicography and HPV testing as optional screening tools in Latin America. Study design and baseline data of the LAMS study. *Anticancer Res* **2005**
36. Franco EL. primary screening of cervical cancer with human papillomavirus tests. *J Natl Cancer Inst Monogr* (31): 89–96, Chap 13, **2003**
37. Cronje HS, Parham GP, Cooreman BF, et al. A comparison of four screening methods for cervical] neoplasia in a in a developing country. *Am J of Obstet Gynecol* 188: 395-400, **2003**
38. World Health Organization, comprehensive cervical cancer control: A guide to essential practice 15-191, **2006**
39. Smith RA, Cokkinides V, Brooks D, Saslow D, Brawley OW. Cancer screening in the United States: a review of current American Cancer Society guidelines and issues in cancer screening. *CA Cancer J Clin* 60: 99-119, **2010**
40. Goldie SJ, Kuhn L, Denny L, Pollack A, Wright TC. Cost-effectiveness of cervical-cancer screening in five developing countries. *N Engl J Med* 353:2158–2168, **2005**
41. Mandelblatt JS, Lawrence WF, Gaffikin L, et al. Costs and benefits of different strategies to screen cervical cancer in less-developed countries. *J Natl Cancer Inst* 94: 1469- 1483, **2002**

Rajshahi University Library
Accession No: D-3706
Date: 15/12/2014
Price: gift
Source: COE, R.U.

APPENDIX-I

Published / communicated work:

Published works:

1. Yusuf N, Islam F, Akhter H, Ali M A, Khanam JA. Early Detection of Cervical Intraepithelial Lesions by Simple Visual Inspection after Acetic Acid among Women in Rajshahi Medical College Hospital. Bangladesh Journal of Medical science Vol. 10 No. 04, pp 240-244; **2011**
2. Yusuf N, Ali M A, Islam F, Akhter H, Khanam JA. Screening of cervical cancer by VIA among Women in Rajshahi Medical College Hospital. Asian Pacific Journal of Tropical Disease pp 70-72; **2012**

Communicated work:

3. Yusuf N, Islam F, Akhter H, Ali M A, Khanam JA. Evaluation of HPV-DNA Test in Detection of Precancerous and Cancerous Lesions of Cervix- Accepted for publication in Asian Journal of Medical Science, Maxwell scientific Organization, Faisalabad, Pakistan, **2012**.

Article # 4533-AJMS-DOI

APPENDIX-II

Future Prospect of the Study

1. A broad based public awareness campaign among clinicians and paramedical staff to be done to encourage them to disseminate knowledge and awareness of the program in the community.
2. To convert the program from one based on opportunistic screening to one with population-based, organized, systematic screening that proactively ensures women attend.
3. As regards clinical care, we need to improve the links between screening, diagnosis and treatment and to fully equip colposcopy clinics with approachable treatment facilities.
4. To maintain the quality of the services, ongoing training, supervision and monitoring are essential. The only solution is to continue training providers and setting up enough centers at the different levels of the health system, so that no matter where a woman is; the services will be available to her.

APPENDIX-III

Data collection proforma:

Patients Profile

Consent: Do you agree to participate in the study? Yes / No

Case no

Reg. no

Date

Particulars of the patient:

Name:

Age:

Address:

Tele no:

Education: Illiterate -1, primary level -2, SSC -3, HSC -4, >HSC -5

Religion: Islam-1, Hindu-2, Others-3

Occupation:

Occupation of the patient:

Husbands Occupation:

Marital status: Married/ divorced/ widow

Social status:

Poor (income <3000/- per month)

Lower middle (income 3000/- 6000/- per month)

Middle (income > 6000/- 10,000/- per month)

Upper >10,000 per month

Risk factors:

Age at first marriage:

Year of marriage

Extramarital exposure: Yes / No

Use of oral contraceptive pill: Yes / No

H/O smoking: Yes / No

No of parity: <2 / 2 / > 2

M.R/ Abortion:

Clinical presentation:

Vaginal discharge: Whitish / Red / Brown / Watery

Abnormal P/V bleeding: Yes / No

Postcoital bleeding: Yes / No

Lower abdominal pain: Yes / No

Others:

Local examination:

Any growth arising or coming through the cervix: Yes / No

Presence of any cervical ulceration: Yes / No

Others:

Have you participated in Pap or other related test? Yes / No

Description of the tests:

VIA test:

Reg. no-

Date-

Findings-

Colposcopic findings:

Reg. no-

Date-

Findings-

Histopathological reports:

Lab no-

Comments

Date-

Pap smear cytology:

Lab no-

Findings-

Date-

HPV DNA test:

Lab no-

Findings-

Date-

Rajshahi University Library
Accession No: D-3706
Date: 15/12/2014
Price: 35/-
Source: COEIR-U